

Post Thyroidectomy US Technologist Worksheet

St Vincents Riverside Southside Clay St Johns Imaging Center Arlington ER Westside ER Beach ER
Optimal Forbes Southside Clay Mandarin Westside St Johns Town Center Orange Park

Patient Name:

MMI:

Age:

History/Symptoms:

Side of Cancer

Right

Left

Thyroidectomy

Right

Left

Date:

Positive Nodes

N

Y

Radioiodine

N

Y

Date:

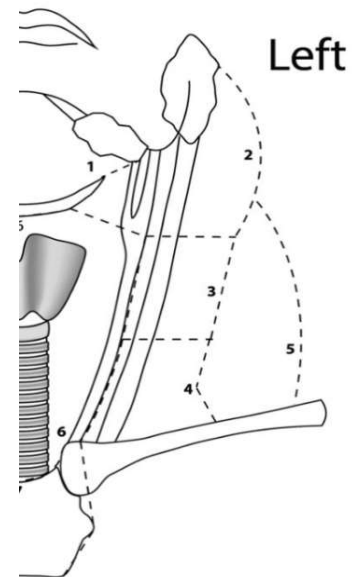
THYROIDECTOMY BED *(residual thyroid tissue, nodules/masses, nodes)*

No Findings

Positive Findings

CERVICAL LYMPH NODES

Indicate side, level and size of any abnormal appearing nodes.



Features that favor a **benign lymph node** include: less than 10 mm in short-axis and elongated or kidney bean shaped (although level II nodes can measure up to 15 mm in short-axis and be more rounded) and have a thin homogeneous hypoechoic cortex surrounding an echogenic hilum.

Features that favor a **malignant lymph node** include: larger in size, more rounded in shape, eccentric cortical thickening, irregular or nodular borders, loss of the echogenic hilum, increased echogenicity relative to adjacent muscle and peripheral blood flow. Lymph nodes containing calcifications or areas of cystic change are almost always malignant.

Sonographer's Impression:

Sonographer's Name, Date & Time:

Images

Not Intended for Treatment Planning

MI-0624
(Revised 6/2025)

Tech Wrksht - "Post Thyroidectomy US Chrtform"