

Brain for Seizure

Updated
11/19/2023

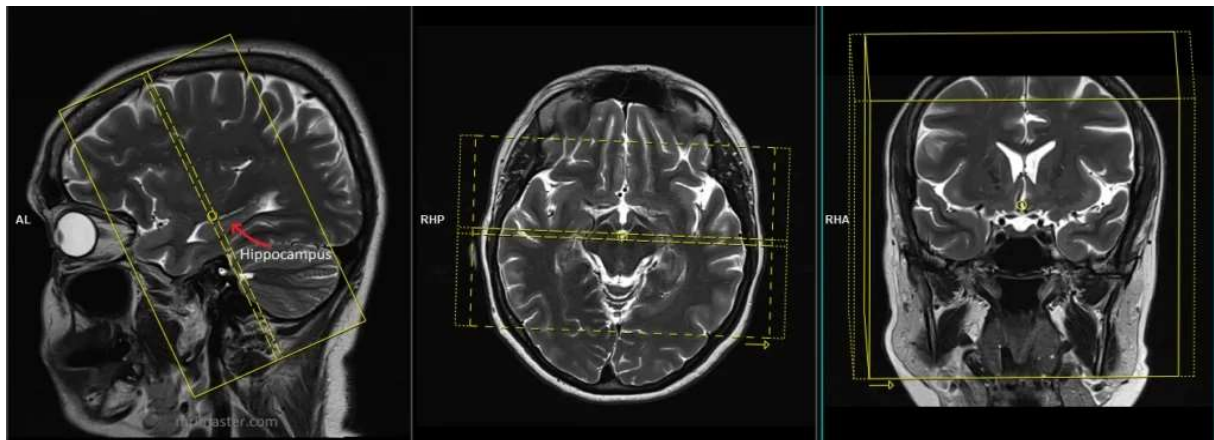
Use temporal lobes field-of-view (FOV) and angulations as in the images below.
Go to MRIMaster.com for a guide of proper positioning.

Pulse Sequence	PACS Name	plane	fat sat	slice (mm)	gap (mm)	first slice	Field of View
T1	T1 SAG	sag	no	5	2	left	whole brain
T2	T2 FS AX	ax	yes	5	1.5	base	
T1	T1 AX	ax	no	5	1.5	base	
FLAIR	FLAIR AX	ax	no	5	1.5	base	
*SWI	SWI AX	ax	no	5	1.5	base	
DWI	DWI AX	ax	yes	5	1.5	base	
T2	T2 COR THINS	cor	no	3	0.2	ant	temporal lobes
FLAIR	FLAIR COR THINS	cor	no	3	0.5	ant	

CONTRAST - 2 mL/sec standard dose gadolinium (0.2 mL/kg Clariscan or 0.1 mL/kg Gadavist) followed by 20 mL saline flush.

T1	T1 POST AX	ax	no	5	1.5	base	whole brain
T1	T1 POST COR	cor	no	5	1.5	ant	

*GRE if SWI is not available.



coronal FOV and angulation (perpendicular to the long axis of the hippocampus in the sagittal plane)

Temporal lobe coronal plane is perpendicular to the long axis of the hippocampus on sagittal images and perpendicular to the midline on coronal images (see image below).

Cover the entire temporal lobes front to back.