

Lumbar Plexus

Updated

11/19/2023

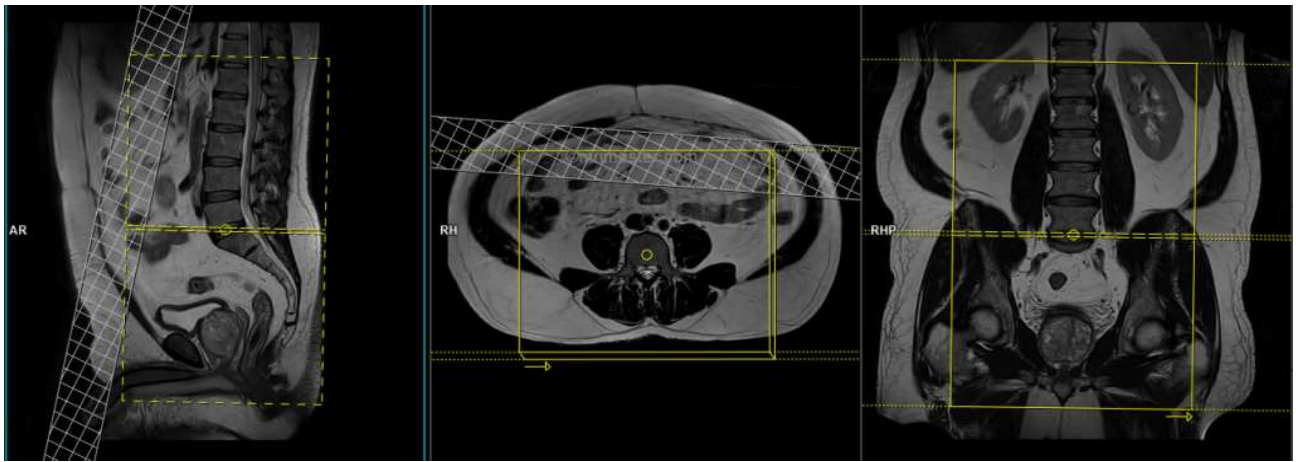
Use lumbar plexus field-of-view (FOV) and angulations as in the images on the **NEXT PAGE**.

Go to MRIMaster.com for a guide of proper positioning.

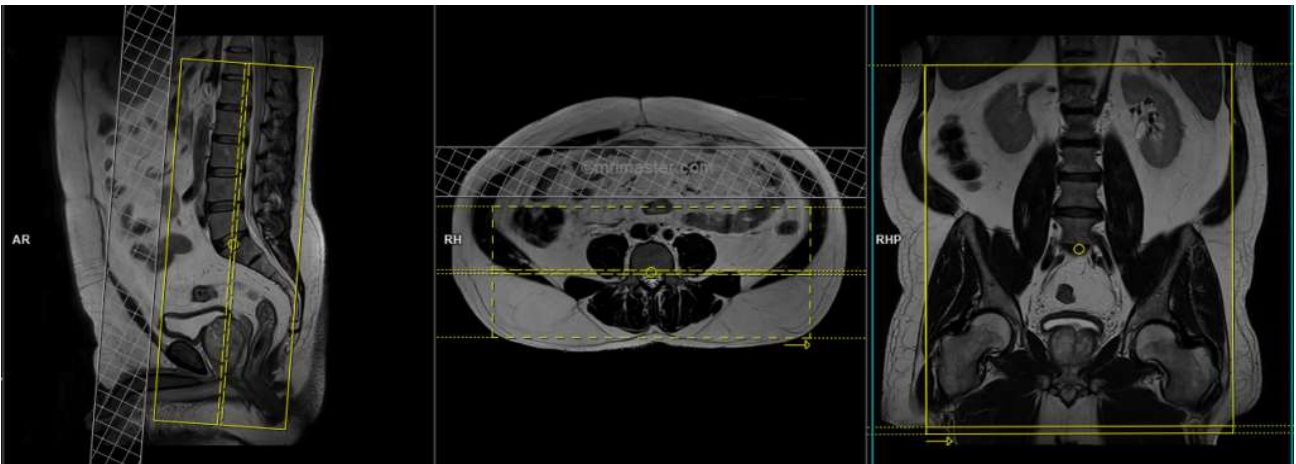
Pulse Sequence	PACS Name	plane	fat sat	slice (mm)	gap (mm)	first slice
T1	T1 AX	ax	no	6	1.2	base
T1	T1 COR	cor	no	5	1	ant
T2	T2 FS AX	ax	yes	6	1.2	base
T2	T2 FS COR	cor	yes	5	1	ant
T2	T2 SAG	sag	no	6	1.2	left

CONTRAST - 2 mL/sec standard dose gadolinium (0.2 mL/kg Clariscan or 0.1 mL/kg Gadavist) followed by 20 mL saline flush.

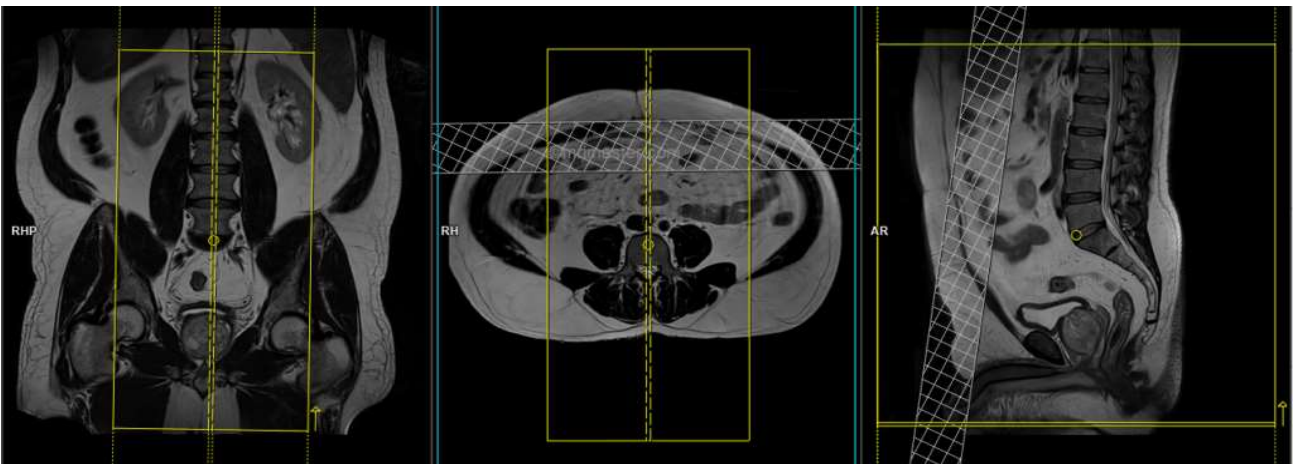
T1	T1 FS POST AX	ax	yes	6	1.2	base
T1	T1 FS POST COR	cor	yes	5	1	ant



axial FOV & angulation (perpendicular to the spinal cord in the sagittal plane)



coronal FOV & angulation (parallel to the spinal cord in the sagittal plane)



sagittal FOV & angulation (parallel to the spinal cord in the coronal plane)