

Ankle/Hindfoot

Updated

2/10/2020

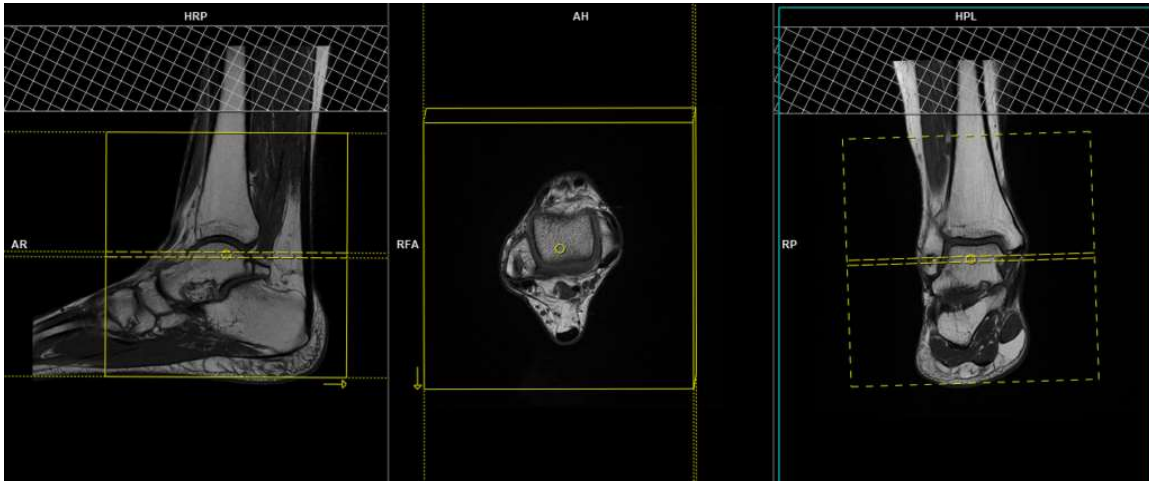
Use field-of-view (FOV) and angulations as in the images on the **NEXT PAGE**.

Go to MRIMaster.com for a guide of proper positioning.

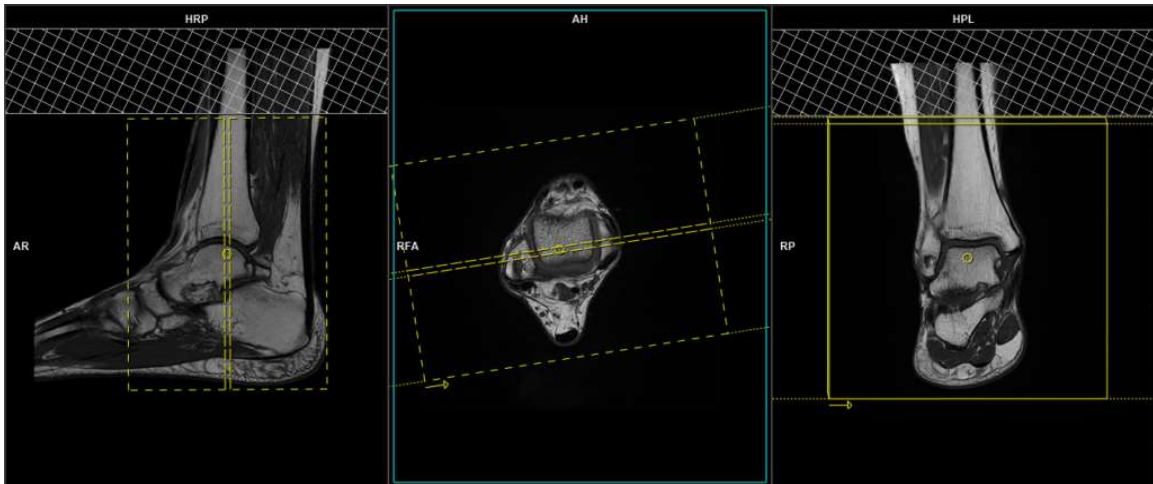
Pulse Sequence	PACS Name	plane	fat sat	slice (mm)	gap (mm)	first slice
T1	T1 SAG	sag	no	3	0.3	lateral
PD	PD FS SAG	sag	yes	3	0.3	lateral
PD	PD AX	ax	no	4	0.5	top
PD	PD FS AX	ax	yes	4	0.5	top
T2	T2 FS AX	ax	yes	4	0.5	top
T1	T1 COR	cor	no	4	0.5	front
DESS/PD	DESS FS COR / PD FS COR	cor	yes	4	0.5	front

CONTRAST - 2 mL/sec standard dose gadolinium (0.2 mL/kg Clariscan or 0.1 mL/kg Gadavist) followed by 20 mL saline flush.

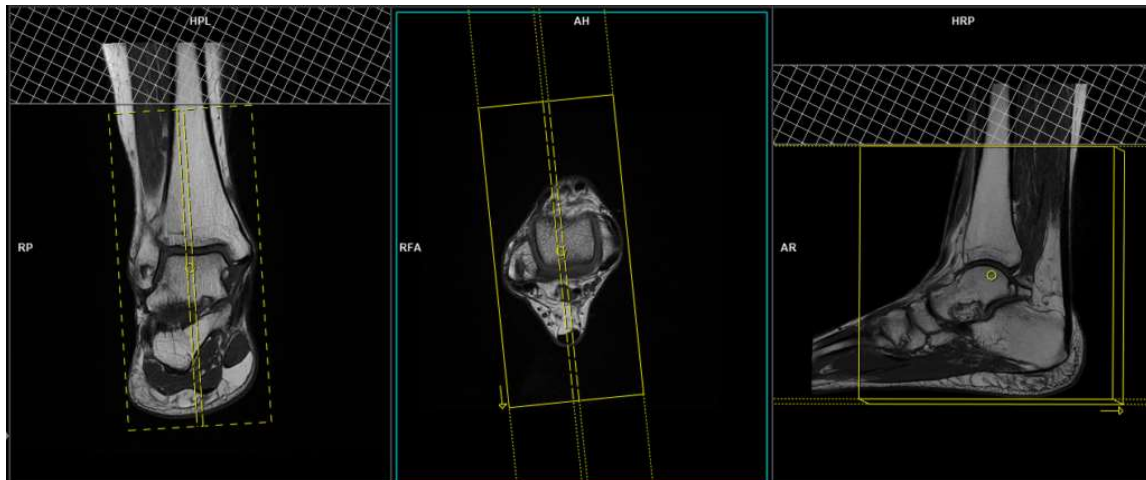
T1	T1 FS POST AX	ax	yes	4	0.5	top
T1	T1 FS POST COR	cor	yes	4	0.5	front
T1	T1 FS POST SAG	sag	yes	3	0.3	sag



axial FOV and angulation (parallel to the tibio-talar joint in the coronal plane)



coronal FOV and angulation (parallel to the line along the medial and lateral malleoli in the axial plane)



sagittal FOV and angulation (perpendicular to the pectoralis muscle in the axial plane)