

# Prostate

Updated

11/4/2023

Indications: prostate cancer and other prostate issues.

Full Pelvis FOV: Iliac crests to few slices below introitus/anus (top/bottom coverage), greater trochanter to greater trochanter (right/left coverage), anterior pelvic wall skin to posterior buttock skin (front/back coverage).

Prostate FOV: cover few slices beyond prostate and seminal vesicles in every plane.

T2 TSE: FOV 12-20 cm, in plane resolution  $\leq 0.7$  mm (phase) x  $\leq 0.4$  mm (frequency)

DWI: FOV 16-22 cm, in plane resolution  $\leq 2.5$  mm (phase) x  $\leq 2.5$  mm (frequency), TE  $\leq 90$  msec, TR  $\geq 3000$  msec

Dynamic T1 post: FOV 12-20 cm, in plane resolution  $\leq 2$  mm (phase) x  $\leq 2$  mm (frequency), TE  $< 5$  msec, TR  $< 100$  msec

Go to MRIMaster.com for a guide of proper positioning.

Pulse Sequence	PACS Name	plane	fat sat	slice (mm)	gap (mm)	first slice	Field of View
----------------	-----------	-------	---------	------------	----------	-------------	---------------

**GLUCAGON** - 1 mg slow IV push **just before** beginning imaging.

T2 TSE	T2 SAG	sag	no	3	0	right	prostate & seminal vesicles
T2 TSE	T2 OBL AX	obl ax	no	3	0	top	
T2 TSE	T2S OBL COR	obl cor	no	3	0	cor	
Diffusion (b50, b800, b1400, ADC)	DIFFUSION OBL AX	obl ax	yes	6	1	top	
T2 HASTE/SSFSE	T2 AX	ax	no	7	1.4	top	full pelvis
T2 HASTE/SSFSE	T2 FS AX	ax	yes	7	1.4	top	
T1 TSE	T1 AX	ax	no	8	2	top	
T1 VIBE/LAVA	T1 FS PRE	ax	yes	3.5	0.6	top	

**GLUCAGON** - 1 mg slow IV push **just before** giving IV contrast.

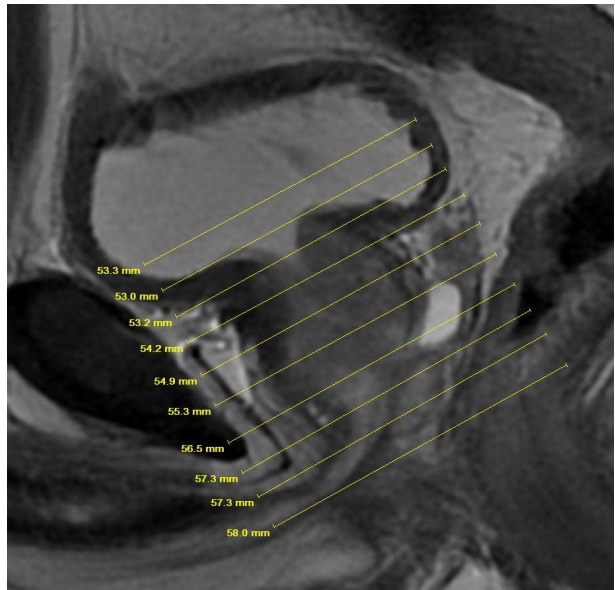
**CONTRAST** - 2 mL/sec standard dose gadolinium (0.2 mL/kg Clariscan or 0.1 mL/kg Gadavist) followed by 20 mL saline flush.

*T1 VIBE/LAVA	T1 FS DYNAMIC	obl ax	yes	3	0	top	prostate & seminal vesicles
T1 VIBE/LAVA	T1 FS POST AX	ax	yes	3.5	0.6	top	full pelvis
T1 VIBE/LAVA	T1 FS POST SAG	sag	yes	3.5	0.6	right	
T1 VIBE/LAVA	T1 FS POST COR	cor	yes	3.5	0.6	front	

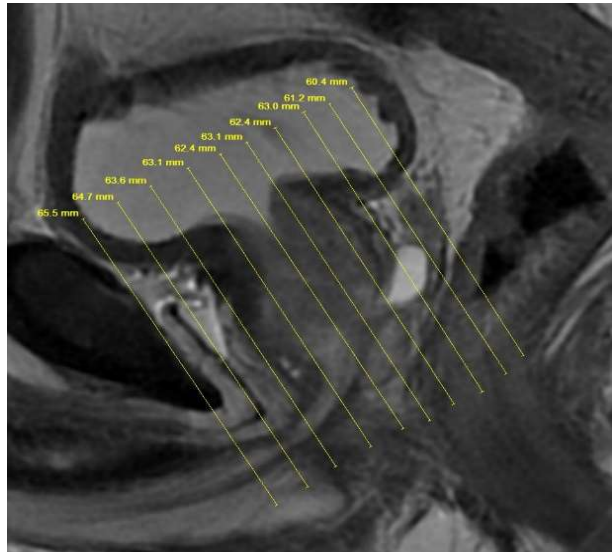
\*Dynamic post contrast phase is axial block every 7-10 secs beginning at injection and continuing for 2-3 mins (similar to the dynamics in pituitary MR).

## RECONS:

axial subtractions of the dynamic phases and axial whole pelvis



oblique axial angulation (perpendicular to the long axis of the prostate in the sagittal plane)



oblique coronal angulation (perpendicular to the long axis of the prostate in the sagittal plane)