

Perianal Fistula

Updated

11/4/2023

Indications: perianal fistula.

There is a separate protocol for fistulas involving the rectum, colon, bladder or vagina.

Have the patient empty his/her bladder just before getting on the table.

Full Pelvis FOV: Just above bifurcation to few slices below introitus/anus (top/bottom coverage), greater trochanter to greater trochanter (right/left coverage), anterior pelvic wall skin to posterior buttock skin (front/back coverage).

Anal canal oblique axial T2 HiRes FOV: centered on anus, FOV 15-20 cm, 256 x 256 matrix, few slices above anus to few slices below anus.

Anal canal oblique coronal T2 Hires FOV: centered on anus, FOV 15-20 cm, 256 x 256 matrix, few slices anterior to anus to few slices posterior to anus.

Go to MRIMaster.com for a guide of proper positioning.

Pulse Sequence	PACS Name	plane	fat sat	slice (mm)	gap (mm)	first slice	Field of View
----------------	-----------	-------	---------	------------	----------	-------------	---------------

GLUCAGON - 1 mg slow IV push **just before** beginning imaging.

T2 TSE	T2 SAG	sag	no	4	1	right	full pelvis
T2 TSE	T2 AX	ax	no	3	0	top	
T2 TSE	T2 OBL AX	obl ax	no	3	0	top	anal canal
T2 TSE	T2 FS OBL AX	obl ax	yes	3	0	top	
T2 TSE	T2 OBL COR	obl cor	no	4	0	front	
T1 VIBE/LAVA	T1 FS PRE SAG	sag	yes	3.5	0.6	right	full pelvis
T1 VIBE/LAVA	T1 FS PRE COR	cor	yes	3.5	0.6	front	
T1 VIBE/LAVA	T1 FS PRE AX	ax	yes	3.5	0.6	top	

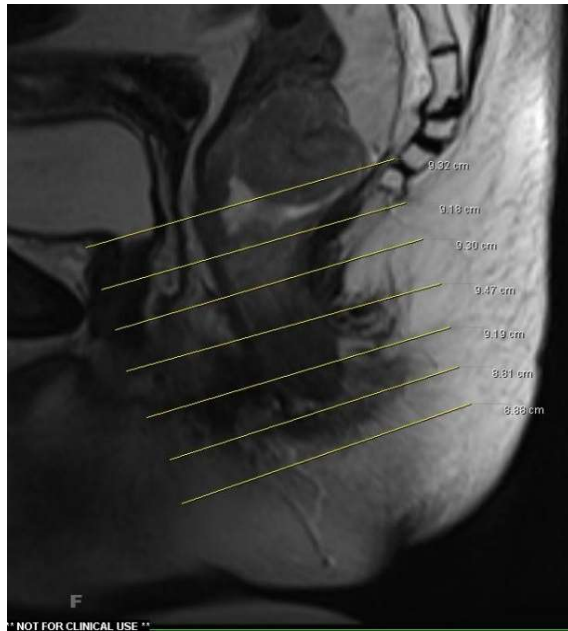
GLUCAGON - 1 mg slow IV push **just before** giving IV contrast.

CONTRAST - 2 mL/sec standard dose gadolinium (0.2 mL/kg Clariscan or 0.1 mL/kg Gadavist) followed by 20 mL saline flush.

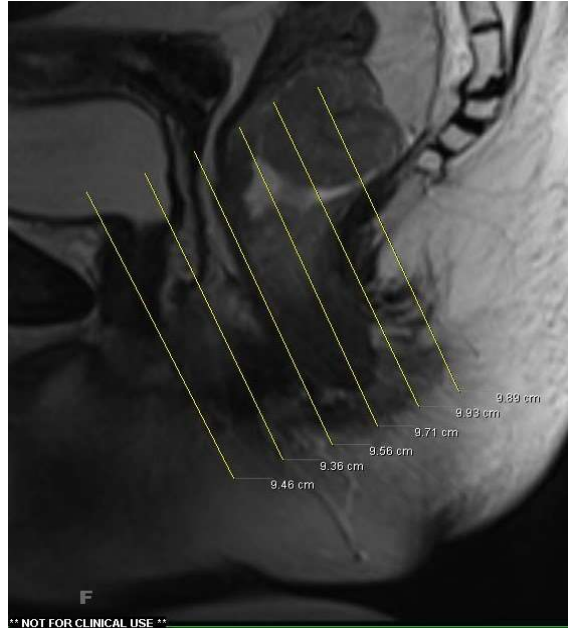T1 VIBE/LAVA	T1 FS 35 SEC AX	ax	yes	3.5	0.6	top	full pelvis
T1 VIBE/LAVA	T1 FS 70 SEC AX	ax	yes	3.5	0.6	top	
T1 VIBE/LAVA	T1 FS POST SAG	sag	yes	3.5	0.6	right	
T1 VIBE/LAVA	T1 FS POST COR	cor	yes	3.5	0.6	front	
Diffusion (b50, b800, ADC)	DIFFUSION AX	ax	yes	6	1	top	

RECONS:

axial, sagittal and coronal subtractions



oblique axial angulation (perpendicular to the long axis of the anal canal in the sagittal plane)



oblique coronal angulation (parallel to the long axis of the anal canal in the sagittal plane)