

CT Ankle/Hindfoot

Updated
5/5/2024

Indications - trauma, fracture, dislocation, pain, bone tumor, soft tissue mass, infection, abscess, soft tissue gas, osteomyelitis, pre/post surgical evaluation.

Bill under CT Ankle charges.

GENERAL SCAN NOTES

Remove any metal from the imaging field of view.

Patient positioning:

Have opposite leg bent at knee with ankle/foot out of way of ankle of interest.

Foot must be dorsiflexed with foot perpendicular to tibia (see images at end of protocol).

Topogram - distal tibia through bottom of foot.

Craniocaudal scan coverage - 3 cm above ankle joint through skin of ball of foot.

Base of metatarsals through skin over Achilles tendon (front/back coverage).

Adjust FOV (field of view) on topogram to smallest without cropping anatomy.

IV Contrast: 100 mL Omnipaque-300, inject at 2.5 mL/sec, 60 secs scan delay.

For **GE scanners**, it is essential for the 1st recon thickness on the scanner to match the 1st recon thickness in this protocol book for the prescribed Noise Index to be valid. The 1st recon should generally be the thickest recon in the protocol.

SIEMENS PARAMETERS & RECONS

	Scan Mode	kV	mAs	Care Dose	Care kV & Lvl	Pitch	Acq	Coll	Rot Time	Scan Time
Sensation 16	spiral	120	120	on	NA	0.55	16	0.75	1.0	5.3
Go Up 32	spiral	Sn 110	366	on	on 75	0.40	32	0.7	1.0	3.9
Sensation 64	spiral	120	120	on	NA	0.90	64	0.6	1.0	2.0
Definition 64	spiral	120	100	on	off	0.80	64	0.6	1.0	2.3
Go Top 64	spiral	Sn 100	898	on	on 75	0.40	64	0.6	1.0	2.3
Drive 128	spiral	120	70	on	off	0.80	128	0.6	1.0	1.1
Force 192	spiral	120	70	on	off	0.80	192	0.6	1.0	0.8

Name of Series	Thick	Interval	Kernel	Window	IR Lvl	Recon Direction
AX BONE	2.0	2.0	Br59 / B60f	bone/osteo	3	head/feet
COR BONE	2.0	2.0	Br59 / B60f	bone/osteo	3	front/back
SAG BONE	2.0	2.0	Br59 / B60f	bone/osteo	3	left/right
AX SOFT	2.0	2.0	Br40 / B31f	abdomen	3	head/feet

Send the above recons on the pre contrast scan (if without only) or on the post contrast scan (if IV given).

Send only the following recon on the pre contrast scan (if without and with).

AX SOFT PRE	2.0	2.0	Br40 / B31f	abdomen	3	head/feet
-------------	-----	-----	-------------	---------	---	-----------

CT Ankle/Hindfoot

GE PARAMETERS & RECONS

	Scan Type	SFOV	kV	mA Range	Noise Index	Smart mA	Slice Thick	Beam Coll	Pitch	Speed	Rot Time	Dose Red	ASIR	Scan Time
LS 16	helical	large	120	100-440	17.68	on	1.25	10	0.938	9.37	0.5	NA	NA	1.9
Opt 540	helical	large	120	100-440	17.68	on	1.25	10	0.938	9.37	0.5	NA	NA	1.9
LS VCT 64	helical	large body	120	100-450	22.63	on	1.25	40	0.984	39.37	0.5	20	20	0.4
Disc VCT 64	helical	large body	120	100-450	22.63	on	1.25	40	0.984	39.37	0.5	NA	NA	0.4

Name of Series	Thickness	Interval	Recon Algorithm	Window Width/Level	Recon Direction
AX BONE	1.25	1.25	bone full	2500/480	head/feet
COR BONE	1.25	1.25	bone full	2500/480	front/back
SAG BONE	1.25	1.25	bone full	2500/480	left/right
AX SOFT	1.25	1.25	std full	400/40	head/feet

Must be first recon.

Send the above recons on the pre contrast scan (if without only) or on the post contrast scan (if IV given).

Send only the following recon on the pre contrast scan (if without and with).

AX SOFT PRE	1.25	1.25	std full	400/40	head/feet
-------------	------	------	----------	--------	-----------

PHILIPS PARAMETERS & RECONS

	Scan Mode	kV	Avg mAs	Dose Index	3D Dose	Pitch	Detect	Colli	Rot Time	Scan Time
Incisive 128	helical	120	85	32	on	0.80	64	0.625	1.00	1.1

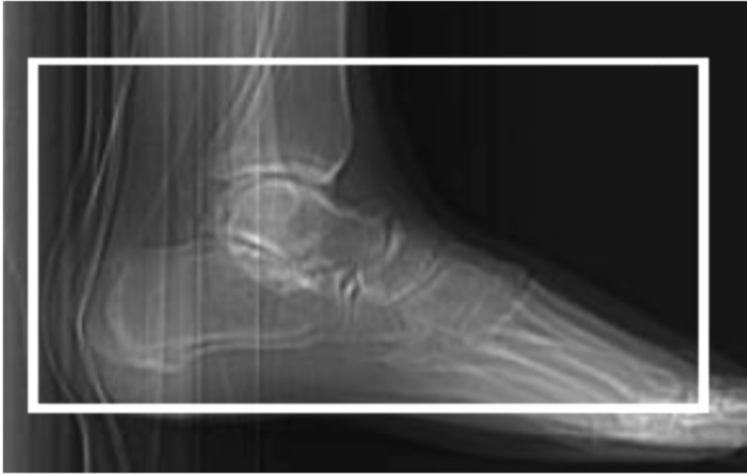Name of Series	Thick	Interval	Filter	Window	iDose	Recon Direction
AX BONE	2.0	2.0	YC	bone	3	head/feet
COR BONE	2.0	2.0	YC	bone	3	front/back
SAG BONE	2.0	2.0	YC	bone	3	left/right
AX SOFT	2.0	2.0	B	abdomen	3	head/feet

Send the above recons on the pre contrast scan (if without only) or on the post contrast scan (if IV given).

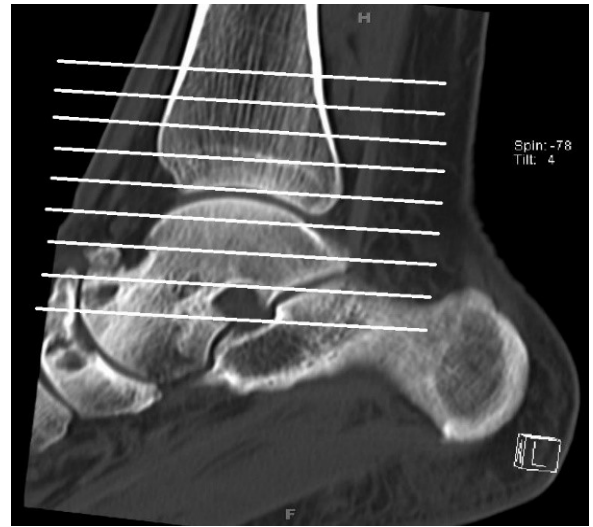
Send only the following recon on the pre contrast scan (if without and with).

AX SOFT PRE	2.0	2.0	B	abdomen	3	head/feet
-------------	-----	-----	---	---------	---	-----------

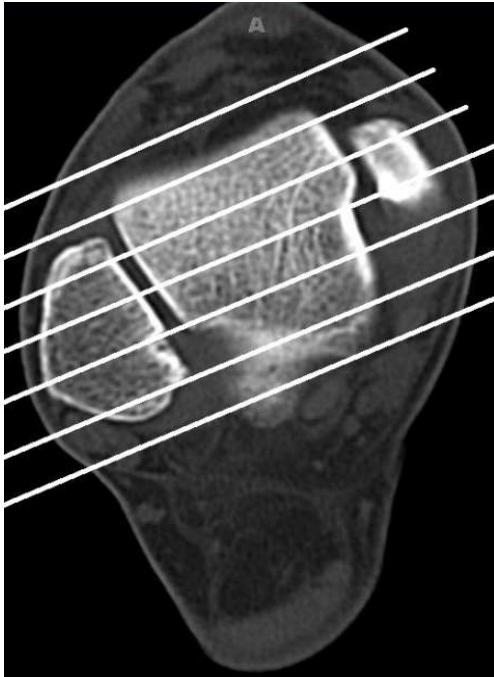
CT Ankle/Hindfoot



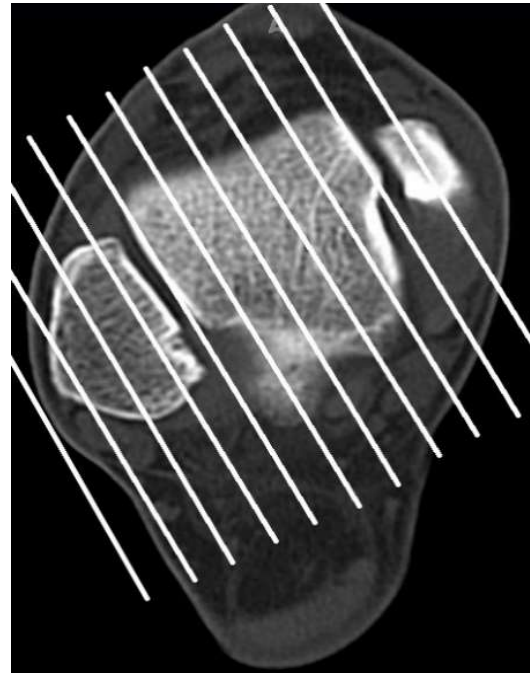
Foot must be dorsiflexed with foot perpendicular to tibia.



Axial Plane



Coronal Plane



Sagittal Plane