

Managing Incidental Findings on Thoracic CT: Mediastinal and Cardiovascular Findings. A White Paper of the ACR Incidental Findings Committee




Reginald F. Munden, MD, DMD, MBA^a, Brett W. Carter, MD^b, Caroline Chiles, MD^c, Heber MacMahon, MB, BCh^d, William C. Black, MD^e, Jane P. Ko, MD^f, H. Page McAdams, MD^g, Santiago E. Rossi, MD^h, Ann N. Leung, MDⁱ, Phillip M. Boiselle, MD^j, Michael S. Kent, MD^k, Kathleen Brown, MD^l, Debra S. Dyer, MD^m, Thomas E. Hartman, MDⁿ, Eric M. Goodman, MD^o, David P. Naidich, MD^p, Ella A. Kazerooni, MD^q, Lincoln L. Berland, MD^r, Pari V. Pandharipande, MD, MPH^s

Credits awarded for this enduring activity are designated “SA-CME” by the American Board of Radiology (ABR) and qualify toward fulfilling requirements for Maintenance of Certification (MOC) Part II: Lifelong Learning and Self-assessment. To access the SA-CME activity visit <https://cortex.acr.org/Presenters/CaseScript/CaseView?CDId=dd5Gx8PRDgk%3d>.

Abstract

The ACR Incidental Findings Committee presents recommendations for managing incidentally detected mediastinal and cardiovascular findings found on CT. The Chest Subcommittee was composed of thoracic radiologists who developed the provided guidance. These recommendations represent a combination of current published evidence and expert opinion and were finalized by informal iterative consensus. The recommendations address the most commonly encountered mediastinal and cardiovascular incidental findings and are not intended to be a comprehensive review of all incidental findings associated with these compartments. Our goal is to improve the quality of care by providing guidance on how to manage incidentally detected thoracic findings.

Key Words: Mediastinal lymph nodes, coronary artery calcification, incidental finding, mediastinum, cardiovascular

J Am Coll Radiol 2018;15:1087-1096. Copyright © 2018 American College of Radiology

^aDepartment of Radiology, Wake Forest School of Medicine, Winston-Salem, North Carolina.

^bThe University of Texas MD Anderson Cancer Center, Houston, Texas.

^cWake Forest University Health Sciences Center, Winston-Salem, North Carolina.

^dThe University of Chicago, Chicago, Illinois.

^eDartmouth-Hitchcock Medical Center and Geisel School of Medicine at Dartmouth, Lebanon, New Hampshire.

^fNYU Langone Health, New York, New York.

^gDuke University, Durham, North Carolina.

^hCentro Rossi, Buenos Aires, Argentina.

ⁱStanford University Medical Center, Stanford, California.

^jCharles E. Schmidt College of Medicine, Florida Atlantic University, Boca Raton, Florida.

^kBeth Israel Deaconess Medical Center, Division of Thoracic Surgery and Interventional Pulmonology, Boston, Massachusetts.

^lDavid Geffen School of Medicine at UCLA, Los Angeles, California.

^mNational Jewish Health, Denver, Colorado.

ⁿMayo Clinic, Rochester, Minnesota.

^oDonald and Barbara Zucker School of Medicine at Hofstra Northwell, Manhasset, New York.

^pNYU-Langone Medical Center, New York, New York.

^qUniversity of Michigan Medical School, Ann Arbor, Michigan.

^rProfessor Emeritus, University of Alabama at Birmingham, Birmingham, Alabama.

^sMassachusetts General Hospital, Boston, Massachusetts.

Corresponding author and reprints: Reginald F. Munden, MD, DMD, MBA, Wake Forest School of Medicine, Department of Radiology, Medical Center Boulevard, Winston-Salem, NC 27157; e-mail: rmunden@wakehealth.edu.

Reginald F. Munden, MD, DMD, MBA, reports a relationship with Optellum, outside the submitted work. Heber MacMahon, MB, BCh, reports personal fees from Riverain Technology, relationship with Hologic Inc, outside the submitted work, grants from Philips Healthcare, personal fees from GE Healthcare, relationship with Konica-Minolta, outside the submitted work. H. Page McAdams, MD, reports personal fees from Boehringer-Ingelheim, personal fees from Roche (Genentech), personal fees from Novartis, personal fees from Merck, relationship with General Electric outside the submitted work, and Abbott, grants and relationship outside the submitted work with Gilead Sciences, and Teva, personal fees from Bristol Myers Squibb, relationships outside the submitted work with CVS, Johnson and Johnson, Pfizer, Glaxo Smith Kline, Sanofi, personal fees from Quintiles, personal fees from MedQIA, outside the submitted work. Santiago E. Rossi, MD, reports personal fees from Boehringer Ingelheim, outside the submitted work. Lincoln L. Berland, MD, reports consulting fees from Nuance Communications, Inc. Pari V. Pandharipande, MD, MPH, reports a grant from Medical Imaging and Technology Alliance, outside the submitted work. The other authors have no conflicts of interest related to the material discussed in this article.

OVERVIEW OF THE ACR INCIDENTAL FINDINGS PROJECT

The core objectives of the ACR Incidental Findings Project are to (1) develop consensus on patient characteristics and imaging features that are required to characterize an incidental finding; (2) provide guidance to manage such findings in ways that balance the risks and benefits to patients; (3) recommend reporting terms that reflect the level of confidence regarding a finding; and (4) focus future research by proposing a generalizable management framework across practice settings.

THE CONSENSUS PROCESS: MANAGEMENT OF MEDIASTINAL AND CARDIOVASCULAR INCIDENTAL FINDINGS

The current article presents the ACR Incidental Findings Committee (IFC)'s recommendations for the management of incidental mediastinal and cardiovascular findings detected on CT. The process of developing these recommendations included naming an overall Chest Subcommittee chair, who appointed subcommittee members that are recognized experts in thoracic imaging. The scope of incidental thoracic findings was recognized to be large. Therefore, within the Chest Subcommittee, further subgroups were named (here termed "System Subcommittees"). This document addresses mediastinal and cardiovascular findings. The membership of each System Subcommittee is listed in the [Appendix](#).

Each System Subcommittee was tasked to define those incidental findings that were most important to address and to develop corresponding recommendations. Published evidence was used as the primary resource; where evidence was not available, members invoked their collective expertise. The recommendations underwent further review by the chairs of all System Subcommittees, the chair of the overall Chest Subcommittee, the chair of the IFC, and the Body Commission chair. The revised recommendations were then submitted to additional ACR stakeholders to gain input and feedback. Consensus was obtained iteratively after successive reviews and revisions.

After completion of this process, the white papers were finalized. The IFC's consensus processes meet policy standards of the ACR. However, they do not meet any specific, formal national standards. The recommendations do not represent policy of the ACR Practice Guidelines or the ACR Appropriateness Criteria. Our consensus may be termed "guidance" and "recommendations" rather than "guidelines," which has a more formal definition [1].

ELEMENTS OF THE FLOWCHARTS: COLOR CODING

Some algorithms are depicted as flowcharts. Within each flowchart, yellow boxes indicate using or acquiring clinical data (eg, lesion size), green boxes describe recommendations for action (eg, follow-up imaging) and red boxes indicate that workup or follow-up may be terminated (eg, if the finding is presumed to be benign). To minimize complexity, our guidance addresses most—but not all—imaging appearances and clinical scenarios. Radiologists should feel comfortable deviating from the algorithm in circumstances that are not represented in the algorithm, based on the specific imaging appearance of the finding in question and patient characteristics—the algorithm content should be viewed as recommendations and should not be considered as "standard of care."

INCLUSION AND EXCLUSION CRITERIA

Patients for whom our recommendations are applicable include adults (≥ 18 years of age) who are asymptomatic and who have been referred to imaging for a reason that is unrelated to the detected incidental finding. The algorithm should not be applied if signs or symptoms that are related to the finding are present. Radiologists' discretion should be used when considering patients with limited life expectancy and substantial comorbidities.

MEDIASTINUM

We address two common mediastinal incidental findings: lymph nodes and masses.

Lymph Nodes

Nature and Scope of the Problem. The prevalence of incidental enlarged mediastinal lymph nodes on lung cancer and coronary artery disease screening CT scans is 1.0% to 3% [2,3]. In 2008, Jacobs et al reviewed 11 screening studies and determined a 1% to 6% prevalence of incidental mediastinal lymphadenopathy [4].

Reporting Considerations. The following elements should be considered when reporting an incidental mediastinal lymph node detected on CT:

1. Size (short axis)
2. Texture or density (if enlarged)
3. Fluorine-18-2-fluoro-2-deoxy-D-glucose (FDG) activity if on PET/CT examination

Historically, mediastinal lymph nodes have been considered abnormal when ≥ 10 mm in short axis. It is known that in patients with metastatic disease, benign nodes are smaller than malignant nodes [5,6]. However, there is little literature regarding the clinical importance of incidentally detected enlarged nodes. Depending on size, texture, and distribution of the nodes, options include reporting as probably benign needing no follow-up, or indeterminate and recommending follow-up with CT, FDG PET/CT, or biopsy.

Possible etiologies of an incidentally detected enlarged lymph node are numerous. If there are no symptoms, then our flowchart guiding management can be used (Fig. 1). If there is a suspicion of lymphoma (eg, due to classic “B” symptoms), then the flowchart does not apply. In young male subjects with incidental enlarged mediastinal lymph nodes, in addition to lymphoma, metastatic disease from undiagnosed seminoma and nonseminomatous germ cell tumors are of primary concern [7]. In these settings, FDG PET/CT imaging is recommended.

Lymph nodes > 1 cm in short axis have been described in association with numerous other (nonmalignant) diseases, including pneumonia and other thoracic infections, congestive heart failure, granulomatous diseases such as sarcoidosis, and diffuse lung diseases. Stigt et al evaluated patients with incidental mediastinal lymphadenopathy and demonstrated that the majority were due to benign etiologies [8]. In a study by Evison et al, lymph node size was the strongest predictor of etiology, with 15 mm or less always reactive ($n = 16$) and pathologic when greater than 25 mm ($n = 25$) [9]. Enlarged (>2 cm) mediastinal nodes have been described in association with various phases of congestive heart failure [4-6] and numerous interstitial lung diseases, including usual interstitial pneumonia, nonspecific interstitial pneumonia, collagen vascular disease, sarcoidosis, extrinsic allergic alveolitis, respiratory bronchiolitis, cryptogenic organizing pneumonia, and desquamative interstitial pneumonia [10,11]. In interstitial lung disease, the prevalence and extent of lymphadenopathy correlate with the severity of the disease [10,11].

Other features of lymph nodes, such as shape, the presence of a fatty hilum, and calcification, are also important to consider. Most benign nodes have smooth and well-defined borders, show uniform and homogeneous attenuation, and demonstrate a central fatty hilum [12]. The lack of such features, or the loss of them since the previous examination, raises suspicion of a clinically significant condition. In the absence of a known

malignancy resulting in calcification or ossification, such as osteosarcoma, chondrosarcoma, papillary thyroid cancer, mucinous tumors of the gastrointestinal and genitourinary tracts, or previously treated lymphoma, mineralization within lymph nodes is indicative of a benign process such as granulomatous disease due to infection or sarcoidosis.

The role of FDG PET/CT in the evaluation for malignancy of incidental mediastinal lymphadenopathy is uncertain. For instance, in the study by Stigt et al, the majority (25 of 29) of cases evaluated with FDG PET/CT showed increased FDG uptake in the enlarged lymph nodes [8]. False-positive results in oncology patients due to reactive lymphadenopathy in the setting of infectious and inflammatory disease processes are well documented [13,14].

One study of the prevalence of incidental findings on CT pulmonary angiography outlined methods for follow-up of enlarged mediastinal lymph nodes [15]. In this study, using criteria such as (1) greater than 1 cm in short-axis diameter and not associated with parenchymal consolidation, (2) greater than 3 cm (largest diameter), or (3) multiple enlarged mediastinal or hilar lymph nodes, 9% of cases warranted follow-up. In general, when a concurrent infectious or inflammatory disease process is evident, when there is no known malignancy, and when lymph nodes demonstrate other benign features, no further evaluation is necessary. In the absence of such features, correlation with clinical history and consultation with the referring health care provider is recommended to evaluate the necessity of further investigation. Although the role of FDG PET/CT is uncertain in such scenarios, it may be considered to assess the metabolic activity of such nodes before further assessment with surgical or transbronchial tissue sampling with endobronchial ultrasound. Likewise, a follow-up CT may be beneficial to assess stability and significance.

Taking into consideration the limited literature, along with the collective experience of the committee, it is the consensus that incidentally detected lymph nodes < 15 mm (in short axis) in patients with no other findings do not require further evaluation.

Implications of Imaging and Clinical Features. Our algorithm is shown in Figure 1. Common principles include the following:

1. Short-axis size threshold of 15 mm guides the decision process.
2. Pulmonary findings are important in determining management of lymph nodes.
3. Clinical history can be a deciding factor in overall management.

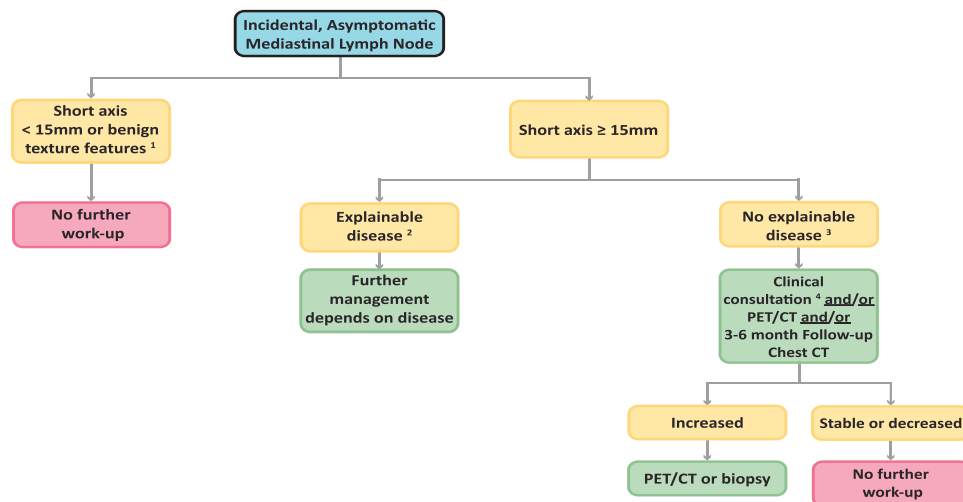


Fig 1. Flowchart for evaluation of an incidentally detected mediastinal lymph node. (1) Short axis measurement is the standard. May consider further action if numerous small lymph nodes are present. (2) Explainable disease such as emphysema, interstitial lung disease, sarcoidosis, cardiac disease. (3) For unexplained causes, consider lymphoma, undiagnosed metastatic disease, including testicular carcinoma in young male, and infection. (4) Clinical consultation with referring provider or specialist.

Mediastinal Masses

Nature and Scope of the Problem. Henschke et al reported a prevalence of prevascular (or anterior mediastinal) masses of 0.4% in 9,263 high-risk smokers over the age of 40 who were evaluated as part of the Early Lung Cancer Action Project [16]; masses <3 cm in diameter remained unchanged or decreased at follow-up CT. More recently, Araki et al assessed the prevalence of prevascular masses on chest CT performed as part of the Framingham Heart Study [17]. Of 2,571 participants, 23 (0.9%) had a solitary prevascular mass; most abnormalities were soft tissue in consistency, and a few contained fat. However, in contrast to the Early Lung Cancer Action Project study, six of eight masses <3 cm demonstrated an increase in size by >20% over 5 to 7 years when compared with prior cardiac CT.

Reporting Considerations. The following elements should be considered when reporting an incidental mediastinal mass detected on CT:

1. Localization to a mediastinal compartment
2. Texture (including cystic versus solid)
3. Evaluation of edge contours (invasion or not)

An incidental mediastinal mass should be localized to a mediastinal compartment, and features such as density, internal components, enhancement, and behavior (aggressive versus nonaggressive) should be assessed to guide management. It is appropriate to utilize the well-known compartment-based (anterior, middle, posterior)

differential diagnosis of mediastinal masses. Here, we address scenarios that commonly cause uncertainty in management. The assessment of anterior and middle masses varies depending on suspected pathology whereas all posterior masses are followed with MRI because of the high likelihood of a nerve origin.

Incidental lesions in the prevascular compartment typically arise from the thyroid gland, the thymus gland, a lymph node, or a benign neoplasm such as a teratoma. Thyroid tissue and teratoma are generally easily diagnosed [18]. A purely cystic lesion is most commonly a thymic cyst. These are typically well-circumscribed, round or oval or saccular, and homogeneous lesions near the thymic bed. However, if they are higher density, MRI is superior to CT in distinguishing cystic versus solid lesions, identifying cystic or necrotic components within solid lesions, and identifying septations or soft tissue components within cystic lesions [19,20]. A well-circumscribed cystic lesion with thin or imperceptible walls in one of the cardiophrenic angles can be confidently diagnosed as a pericardial cyst [21].

A soft tissue mass conforming to the shape of the thymic gland is typically thymic hyperplasia, especially in a young patient [22]. It likely represents rebound hyperplasia if there is a history of chemotherapy, radiation therapy, or corticosteroids; stress, such as burns or injuries; or disorders such as myasthenia gravis, hyperthyroidism, collagen vascular diseases, or AIDS. If the diagnosis is uncertain, chemical shift (opposed-phase) MR imaging can be performed;

follow-up CT in 3 months is considered a reasonable alternative. Thymic hyperplasia and the normal thymus demonstrate loss of signal on out-of-phase imaging due to suppression of microscopic fat interspersed within a nonneoplastic thymus; thymic malignancies and lymphoma do not suppress on out-of-phase imaging [23].

A homogeneous or slightly heterogeneous prevascular soft tissue mass in men and women >40 years likely represents a thymoma, especially if combined with symptoms of myasthenia gravis or another paraneoplastic syndrome [24]. A large, heterogeneous prevascular mediastinal lesion with local invasion, lymphadenopathy, and pleural effusion is most suspicious for an aggressive thymic epithelial neoplasm such as thymic carcinoma or carcinoid [25].

A mildly enhancing lobular soft tissue mass or group of lesions in the prevascular compartment on CT, especially in the setting of lymph nodes in the neck, axilla, or elsewhere in the body, could represent lymphoma. Although differentiating among lymphoma and other mediastinal masses may be difficult, the infiltrative nature of some lymphomas enables differentiation from thymic and germ cell neoplasms. Additionally, lymphoma frequently encases vascular structures and does not result in vascular invasion. When these findings are present in young patients who present with classic “B” symptoms, lymphoma can be reliably diagnosed with tissue sampling.

Implications of Imaging and Clinical Features. Our algorithm is shown in Figure 2. Common principles include:

1. Localization to a mediastinal compartment guides the differential diagnosis.
2. Clinical history can be decisive in determining management.

CARDIOVASCULAR

Here we address four common cardiovascular findings—pericardial sac findings, aortic dilation, coronary artery calcification (CAC), and pulmonary artery dilation—all of which are common on thoracic CT [26-28]. Sverzellati et al reported that 50% of 286 CT examinations performed for pulmonary fibrosis, suspected pulmonary embolism (PE), or lung cancer staging had potentially significant cardiovascular findings [29]. Likewise, Choy et al reported that 61% of consecutive routine chest CT examinations had reportable cardiac findings [30].

Pericardial Sac Findings

Nature and Scope of the Problem. Pericardial fluid is common on CT and is known to be associated with many diseases such as infection, malignancy, trauma, and myocardial disease; it also is commonly seen post-operatively [31-35]. The presence of a large pericardial effusion usually indicates significant disease and warrants reporting [34].

Reporting Considerations. The following elements should be considered when reporting an incidental pericardial sac finding detected on CT:

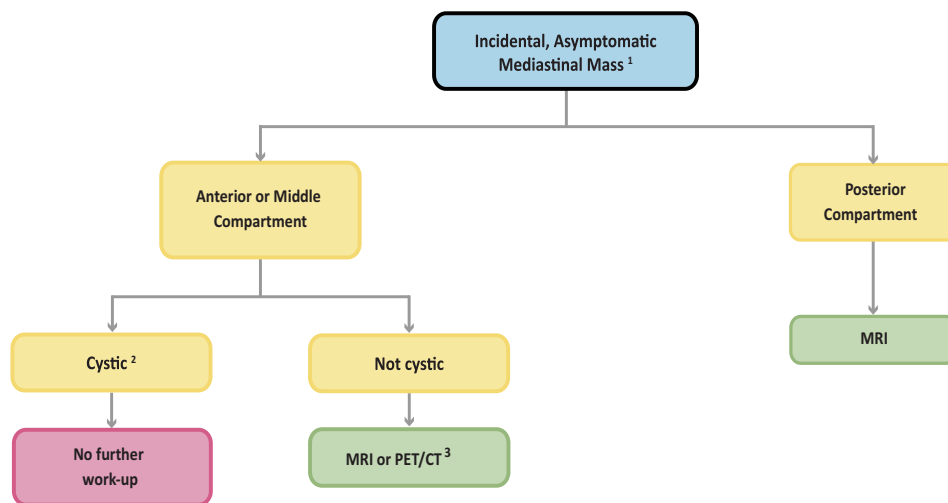


Fig 2. Flowchart for evaluation of an incidentally detected mediastinal mass. (1) Localization most important for the differential diagnosis. (2) Consider benign, but may require resection if large and causing symptoms. (3) Modality depends on suspected etiology or malignancy potential.

1. Fluid volume greater than estimated 50 mL
2. Size and texture of pericardial mass
3. Pericardium thickening

The pericardial sac normally contains between 15 and 30 mL of fluid, which can be recognized as trace amounts of fluid, usually within the pericardial recesses [36]. Up to 50 mL can be physiologic [37,38]. The pericardium is normally seen as a 1- to 2-mm-thick line between the mediastinal and epicardial fat layers. The maximal thickness of the normal pericardium is 2 mm; a thickness of >3 to 4 mm is considered abnormal [37]. Pericardial recesses are commonly seen; it is important to not mistake them for lymphadenopathy [36].

Pericardial cysts are rare, occurring in 1 of 100,000 individuals, but are the most common benign pericardial mass [39]. If of simple fluid attenuation, they do not require further evaluation. Evaluation may be recommended if the cyst is higher in attenuation, particularly if the patient has symptoms such as chest pain. They may hemorrhage or be infected; MRI may be useful to further characterize cyst contents and to assess compression of normal structures.

Implications of Imaging and Clinical Features. Our algorithm is shown in Figure 3. Common principles include the following:

1. Pericardial effusions are common and usually require no further workup. Because of differences in body

habitus, there are no morphologic criteria to determine a volume of 50 mL on CT; therefore, this evaluation is subject to variation. Etiology of large volumes will need clinical correlation.

2. Incidental pericardial cysts do not require follow-up unless they are large and risk compression of adjacent structures.
3. Clinical history may explain a thickened pericardium, precluding the need for further follow-up.

Thoracic Aortic Dilatation and Aneurysm

Nature and Scope of the Problem. Although the prevalence of thoracic aortic aneurysm is low, overall aortic disease is incidentally detected on chest CT in up to 3.4% of cases. In one report, 21 of 22 incidentally detected aortic findings were aneurysms, with the other finding being a dissection [4]. Aneurysmal dilatation (defined later) is the most likely abnormality to be seen, especially with noncontrast CT. Without intravenous contrast, aortic dissections and significant ulcerations are usually undetectable.

Reporting Considerations. The following elements should be considered when reporting incidental aortic dilatation detected on CT:

1. Report and measure thoracic aortic aneurysms, based on the below criteria.

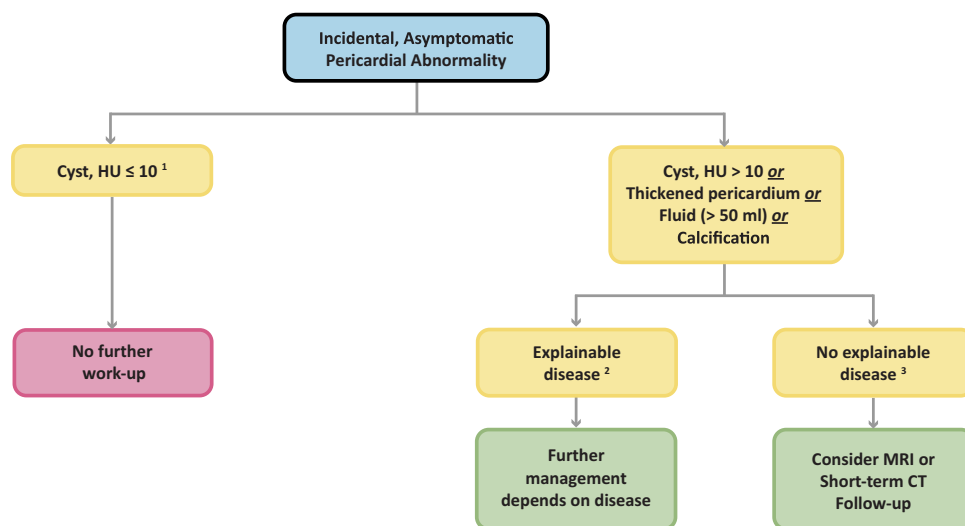


Fig 3. Algorithm for evaluation of an incidentally detected pericardial abnormality. (1) Considered benign, but may require resection if large and impacts cardiac function. (2) Explainable disease such as autoimmune disease, prior radiation therapy, prior infection, history of renal disease, medications. (3) For unexplained causes, consider pericarditis (acute/constrictive and infection), post-myocardial infarction, undiagnosed disease such as metabolic (hypothyroidism, uremic), autoimmune, sarcoidosis.

2. Report anatomic location (ascending, descending).

Aortic diameter is influenced by gender, age, and body surface area. Thoracic aortic size was evaluated on electrocardiogram (ECG)-gated, non-contrast-enhanced multi detector computed tomography scans in 3,431 Framingham Heart Study participants [40]. For men, average diameters were 34.1 ± 3.9 mm for the ascending thoracic aorta and 25.8 ± 3.0 mm for the descending thoracic aorta; for women, average diameters were 31.9 ± 3.5 mm for the ascending thoracic aorta and 23.1 ± 2.6 mm for the descending thoracic aorta [40].

Aortic diameters greater than the upper limits of normal (2 SD above the mean diameter as adjusted for age, sex, and body surface area), but not meeting criteria for aneurysm, may be considered ectatic or dilated. The term *aneurysm* is reserved for diameters that are 150% of normal, which is approximately 5.0 cm for the ascending aorta and 4.0 cm for the descending aorta [41].

In general, aortic diameters of 5.5 cm or larger place patients at high risk for rupture and should be considered for intervention [42-44]. If connective tissue diseases such as Marfan or Ehlers-Danlos disease is known, then a diameter of 5 cm prompts consideration of prophylactic aortic root replacement [45].

Implications of Imaging and Clinical Features.

1. In general, an aneurysm (150% of normal) is defined as approximately 5.0 cm for the ascending and 4.0 cm for descending aorta.
2. Diameters between normal and aneurysm are considered dilated or ectatic.

Coronary Artery Calcification

Nature and Scope of the Problem. CAC was present on 53% of CT examinations performed for noncardiac indications in patients with no history of coronary artery disease [46] in a study by Uretsky and Wolff. Woodring and West reported 41% of patients over 40 years of age had CAC on CT [47]. In a review by Johnson et al, CAC was reported in only 24% of patients who underwent CT angiography for pulmonary embolus [48].

Reporting Considerations. The following elements should be considered when reporting an incidental CAC detected on CT:

1. CAC should be reported when it is likely to affect patient management.

2. CAC can be reported using either the Agatston scoring system or the visual method of none, mild, moderate, or heavy or severe.

CAC is a marker of atherosclerosis that correlates with the extent of atherosclerotic plaque [49,50] and can be used in predicting coronary heart disease risk [51]. CAC can be assessed quantitatively using a number of techniques, including Agatston scoring and mass and volume scores [52-54]. These techniques have been developed using electron beam or multidetector CT, using typical scan techniques that include prospective ECG-gating, 2.5- to 3.0-mm slice thickness, and 120 kVp. In the 2010 American College of Cardiology Foundation/American Heart Association Guideline for Assessment of Cardiovascular Risk in Asymptomatic Adults, a class IIA recommendation (benefit \gg risk, additional studies with focused objectives needed) stated that CAC measurement was reasonable for cardiovascular risk assessment in asymptomatic adults at intermediate risk (10% to 20% 10-year risk) [55]. A class IIB recommendation (benefit $>$ risk, additional studies with broad objectives needed) stated that CAC measurement may be reasonable for cardiovascular risk assessment in persons at low to intermediate risk (6%-10% 10-year risk).

The Society of Cardiovascular Computed Tomography and the Society of Thoracic Radiology issued guidelines in 2016 for reporting CAC on non-contrast-enhanced noncardiac chest CT examinations [56]. These guidelines recommend reporting CAC in all patients irrespective of the scan indication or the patient risk status.

Three scoring methodologies have been utilized for reporting CAC scores on nongated noncontrast chest CTs: Agatston scores [57-60], ordinal scores [57], and visual analysis [57]. The Agatston score on nongated chest CT has been shown to correlate well with gated cardiac CT scores and similarly predicts mortality [58]. It also offers high interreader correlation but requires additional software and time to evaluate. The manually calculated ordinal score also correlates well with mortality but is time-intensive to calculate. The fastest method is visual assessment of CAC as either none, mild, moderate, or heavy or severe [57], which has been shown to correlate well with Agatston scores and with mortality.

The radiology report may also include correlation of CAC scores with coronary heart disease risk: Agatston scores of 0, 1 to 100, 101 to 300, and >300 [61] and

visual scores of none, mild, moderate, and heavy or severe calcifications correlate with very low, mildly increased, moderately increased, and moderately to severely increased risk, respectively [57].

Assessing the presence or absence of CAC on a chest CT performed for reasons other than CAC scoring may be valuable to the patient and referring physician, either for reassurance that no CAC is present or to increase patient awareness of coronary heart disease risk and stimulate discussion of cardiac risk factors. We recommend that radiologists include CAC observations within diagnostic reports of both gated and nongated CT scans, interpreting CAC by the quantitative Agatston score approach or by the qualitative, visual assessment as described previously.

Implications of Imaging and Clinical Features.

1. Reporting the presence or absence of CAC detected on a CT can provide valuable information to the referring clinician and patient.
2. CAC classified as heavy or severe should be further evaluated.

Pulmonary Artery

Nature and Scope of the Problem. Pulmonary artery hypertension (PAH) is a rare disease with a prevalence of 15 to 50 cases per million [62]. It has a higher incidence in some populations such as HIV-infected patients, sickle cell disease, and systemic sclerosis [63-65]. Idiopathic PAH represents at least 40% of cases of PAH and is most frequently diagnosed when advanced [66]. CT is a surrogate marker for PAH [67], and therefore recognition of pulmonary artery dilation by the radiologist is important [68].

Reporting Considerations. The following elements should be considered when reporting incidental pulmonary artery dilation detected on CT:

1. Diameter of the main pulmonary artery, if dilated (based on the below criteria)
2. Location and distribution of pulmonary embolus or emboli, if present

A main pulmonary artery ≥ 3.0 cm, or equal in diameter to the ascending aorta, should be reported as dilated [69]. The diameter of the main pulmonary artery was measured on ECG-gated noncontrast CT in a cohort of 3,171 individuals in the Framingham Heart Study, and the 90th percentile cutoff value was 29 mm in men and 27 mm in women [69]. The 90th percentile cutoff value for the

ratio of the diameter of the main pulmonary artery to the ascending aorta at the same level was 0.91.

Dilation of the main pulmonary artery correlates with increased pulmonary artery pressure. In a study of 298 patients with known pulmonary hypertension and 102 controls [70], applied thresholds of mean main pulmonary artery diameter >29.5 mm and >31.5 mm and ratio of main pulmonary artery diameter to ascending aorta diameter >1.0 were found to have sensitivities of 71%, 52%, and 71% and specificities of 79%, 90%, and 75%, respectively, for pulmonary hypertension. In advanced fibrotic lung disease, retractile forces on the mediastinum may cause dilation of the main pulmonary artery [71].

Unsuspected acute PE has been reported in 0.6% to 4.0% of outpatients and 4% to 6.4% of inpatients on routine contrast-enhanced chest CT [72-75]. Malignancy is the most common predisposing factor, and prevalence is highest among oncology patients [72-75]. The prevalence of unsuspected chronic PE in patients on routine contrast-enhanced CT is unknown; however, chronic thromboembolic disease resulting in pulmonary hypertension occurs in $<1\%$ of patients who are followed after a documented episode of PE [76]. Thrombosis in a pulmonary artery stump postpneumonectomy can occur in up to 12% of patients [77]. Although controversial, anticoagulation is often not initiated unless there are emboli to other sites [78,79].

Implications of Imaging and Clinical Features.

1. A main pulmonary artery ≥ 3.0 cm or more in diameter, or equal in diameter to the ascending aorta, should be reported as dilated.
2. An enlarged pulmonary artery may reflect primary PAH or be secondary to chronic pulmonary embolus or other pulmonary disease.

TAKE-HOME POINTS

- Incidental mediastinal and cardiovascular findings are frequently seen on thoracic CT.
- This white paper provides guidance on the management of six common domains of incidental thoracic findings: mediastinal lymph nodes; mediastinal masses; pericardial sac abnormalities; thoracic aortic dilation; CAC; and pulmonary artery dilation.
- By providing recommendations for managing these incidental mediastinal and cardiovascular findings, our goal is to reduce reporting variability and improve the quality of related imaging care.

ADDITIONAL RESOURCES

Additional resources can be found online at: <https://doi.org/10.1016/j.jacr.2018.04.029>.

REFERENCES

- Berland LL, Silverman SG, Gore RM, et al. Managing incidental findings on abdominal CT: white paper of the ACR incidental findings committee. *J Am Coll Radiol* 2010;7:754-73.
- Gil BN, Ran K, Tamar G, Shmuell F, Eli A. Prevalence of significant noncardiac findings on coronary multidetector computed tomography angiography in asymptomatic patients. *J Comput Assist Tomogr* 2007;31:1-4.
- Vierikko T, Jarvenpaa R, Autti T, et al. Chest CT screening of asbestos-exposed workers: lung lesions and incidental findings. *Eur Respir J* 2007;29:78-84.
- Jacobs PC, Mali WP, Grobbee DE, van der Graaf Y. Prevalence of incidental findings in computed tomographic screening of the chest: a systematic review. *J Comput Assist Tomogr* 2008;32:214-21.
- de Langen AJ, Rajmakers P, Riphagen I, Paul MA, Hoekstra OS. The size of mediastinal lymph nodes and its relation with metastatic involvement: a meta-analysis. *Eur J Cardiothorac Surg* 2006;29:26-9.
- Wiersema MJ, Vazquez-Sequeiros E, Wiersema LM. Evaluation of mediastinal lymphadenopathy with endoscopic US-guided fine-needle aspiration biopsy. *Radiology* 2001;219:252-7.
- Carter BW, Okumura M, Detterbeck FC, Marom EM. Approaching the patient with an anterior mediastinal mass: a guide for radiologists. *J Thorac Oncol* 2014;9:S110-8.
- Stigt JA, Boers JE, Oostdijk AH, van den Berg JW, Groen HJ. Mediastinal incidentalomas. *J Thorac Oncol* 2011;6:1345-9.
- Evison M, Crosbie PA, Morris J, Martin J, Barber PV, Booton R. A study of patients with isolated mediastinal and hilar lymphadenopathy undergoing EBUS-TBNA. *BMJ Open Respir Res* 2014;1:e000040.
- Attili AK, Kazerooni EA, Gross BH, Flaherty KR, Martinez FJ. Thoracic lymph node enlargement in usual interstitial pneumonitis and nonspecific-interstitial pneumonitis: prevalence, correlation with disease activity and temporal evolution. *J Thorac Imaging* 2006;21:288-92.
- Souza CA, Muller NL, Lee KS, Johkoh T, Mitsuhiro H, Chong S. Idiopathic interstitial pneumonias: prevalence of mediastinal lymph node enlargement in 206 patients. *AJR Am J Roentgenol* 2006;186:995-9.
- Torabi M, Aquino SL, Harisinghani MG. Current concepts in lymph node imaging. *J Nucl Med* 2004;45:1509-18.
- Truong MT, Pan T, Erasmus JJ. Pitfalls in integrated CT-PET of the thorax: implications in oncologic imaging. *J Thorac Imaging* 2006;21:111-22.
- Onal C, Oymak E, Findikcioglu A, Reyhan M. Isolated mediastinal lymph node false positivity of [18F]-fluorodeoxyglucose-positron emission tomography/computed tomography in patients with cervical cancer. *Int J Gynecol Cancer* 2013;23:337-42.
- Hall WB, Truitt SG, Scheunemann LP, et al. The prevalence of clinically relevant incidental findings on chest computed tomographic angiograms ordered to diagnose pulmonary embolism. *Arch Intern Med* 2009;169:1961-5.
- Henschke CI, Lee JJ, Wu N, et al. CT screening for lung cancer: prevalence and incidence of mediastinal masses. *Radiology* 2006;239:586-90.
- Araki T, Nishino M, Gao W, et al. Anterior mediastinal masses in the Framingham Heart Study: prevalence and CT image characteristics. *Eur J Radiol Open* 2015;2:26-31.
- Rosado-de-Christenson ML, Templeton PA, Moran CA. From the archives of the AFIP. Mediastinal germ cell tumors: radiologic and pathologic correlation. *Radiographics* 1992;12:1013-30.
- Tomiyama N, Honda O, Tsubamoto M, et al. Anterior mediastinal tumors: diagnostic accuracy of CT and MRI. *Eur J Radiol* 2009;69:280-8.
- Ackman JB, Wu CC. MRI of the thymus. *AJR Am J Roentgenol* 2011;197:W15-20.
- Jeung MY, Gasser B, Gangi A, et al. Imaging of cystic masses of the mediastinum. *Radiographics* 2002;22 Spec No:S79-93.
- Ackman JB, Kovacina B, Carter BW, et al. Sex difference in normal thymic appearance in adults 20-30 years of age. *Radiology* 2013;268:245-53.
- Inaoka T, Takahashi K, Mineta M, et al. Thymic hyperplasia and thymus gland tumors: differentiation with chemical shift MR imaging. *Radiology* 2007;243:869-76.
- Benveniste MF, Rosado-de-Christenson ML, Sabloff BS, Moran CA, Swisher SG, Marom EM. Role of imaging in the diagnosis, staging, and treatment of thymoma. *Radiographics* 2011;31:1847-61; discussion 61-3.
- Rosado-de-Christenson ML, Strollo DC, Marom EM. Imaging of thymic epithelial neoplasms. *Hematol Oncol Clin North Am* 2008;22:409-31.
- Bogaert J, Centonze M, Vanneste R, Francone M. Cardiac and pericardial abnormalities on chest computed tomography: what can we see? *Radiol Med* 2010;115:175-90.
- Lee SH, Seo JB, Kang JW, Chae EJ, Park SH, Lim TH. Incidental cardiac and pericardial abnormalities on chest CT. *J Thorac Imaging* 2008;23:216-26.
- Jairam PM, Gondrie MJ, Grobbee DE, et al. Incidental imaging findings from routine chest CT used to identify subjects at high risk of future cardiovascular events. *Radiology* 2014;272:700-8.
- Sverzellati N, Arcadi T, Salvolini L, et al. Under-reporting of cardiovascular findings on chest CT. *Radiol Med* 2016;121:190-9.
- Choy G, Kropil P, Scherer A, et al. Pertinent reportable incidental cardiac findings on chest CT without electrocardiography gating: review of 268 consecutive cases. *Acta Radiol* 2013;54:396-400.
- Wang ZJ, Reddy GP, Gotway MB, Yeh BM, Herts SW, Higgins CB. CT and MR imaging of pericardial disease. *Radiographics* 2003;23 Spec No:S167-80.
- Blaivas M. Incidence of pericardial effusion in patients presenting to the emergency department with unexplained dyspnea. *Acad Emerg Med* 2001;8:1143-6.
- Spodick DH. The normal and diseased pericardium: current concepts of pericardial physiology, diagnosis and treatment. *J Am Coll Cardiol* 1983;1:240-51.
- Sun JS, Park KJ, Kang DK. CT findings in patients with pericardial effusion: differentiation of malignant and benign disease. *AJR Am J Roentgenol* 2010;194:W489-94.
- Ashikhmina EA, Schaff HV, Sinak LJ, et al. Pericardial effusion after cardiac surgery: risk factors, patient profiles, and contemporary management. *Ann Thorac Surg* 2010;89:112-8.
- Shroff GS, Boonsirikamchai P, Viswanathan C, Godoy MC, Marom EM, Truong MT. Differentiating pericardial recesses from mediastinal adenopathy: potential pitfalls in oncological imaging. *Clin Radiol* 2014;69:307-14.
- Delille JP, Hernigou A, Sene V, et al. Maximal thickness of the normal human pericardium assessed by electron-beam computed tomography. *Eur Radiol* 1999;9:1183-9.
- Ashley EA, Niebauer J. *Cardiology explained*. London: Remedica; 2004. Available from: <https://www.ncbi.nlm.nih.gov/books/NBK2204/>.
- Peebles CR, Shambrook JS, Harden SP. Pericardial disease—atomy and function. *Br J Radiol* 2011;84 Spec No 3:S324-37.
- Rogers IS, Massaro JM, Truong QA, et al. Distribution, determinants, and normal reference values of thoracic and abdominal aortic diameters by computed tomography (from the Framingham Heart Study). *Am J Cardiol* 2013;111:1510-6.
- Hiratzka LF, Bakris GL, Beckman JA, et al. 2010 ACCF/AHA/AATS/ACR/ASA/SCA/SCAI/SIR/STS/SVM Guidelines for the diagnosis and management of patients with thoracic aortic disease. A Report of the American College of Cardiology Foundation/

- American Heart Association Task Force on Practice Guidelines, American Association for Thoracic Surgery, American College of Radiology, American Stroke Association, Society of Cardiovascular Anesthesiologists, Society for Cardiovascular Angiography and Interventions, Society of Interventional Radiology, Society of Thoracic Surgeons, and Society for Vascular Medicine. *J Am Coll Cardiol* 2010;55:e27-129.
42. Davies RR, Goldstein LJ, Coady MA, et al. Yearly rupture or dissection rates for thoracic aortic aneurysms: simple prediction based on size. *Ann Thorac Surg* 2002;73:17-27; discussion 27-8.
 43. Elefteriades JA. Natural history of thoracic aortic aneurysms: indications for surgery, and surgical versus nonsurgical risks. *Ann Thorac Surg* 2002;74:S1877-80. discussion S92-8.
 44. Kouchoukos NT, Dougenis D. Surgery of the thoracic aorta. *N Engl J Med* 1997;336:1876-88.
 45. Milewicz DM, Dietz HC, Miller DC. Treatment of aortic disease in patients with Marfan syndrome. *Circulation* 2005;111:e150-7.
 46. Uretsky S, Wolff SD. Reply: Primum non nocere: first do no harm. *J Am Coll Cardiol* 2015;66:492-3.
 47. Woodring JH, West JW. Coronary artery calcification identified by CT in patients over forty years of age. *Australas Radiol* 1989;33:79-83.
 48. Johnson C, Khalilzadeh O, Novelline RA, Choy G. Coronary artery calcification is often not reported in pulmonary CT angiography in patients with suspected pulmonary embolism: an opportunity to improve diagnosis of acute coronary syndrome. *AJR Am J Roentgenol* 2014;202:725-9.
 49. Mautner GC, Mautner SL, Froehlich J, et al. Coronary artery calcification: assessment with electron beam CT and histomorphometric correlation. *Radiology* 1994;192:619-23.
 50. Rumberger JA, Simons DB, Fitzpatrick LA, Sheedy PF, Schwartz RS. Coronary artery calcium area by electron-beam computed tomography and coronary atherosclerotic plaque area. A histopathologic correlative study. *Circulation* 1995;92:2157-62.
 51. Liu W, Zhang Y, Yu CM, et al. Current understanding of coronary artery calcification. *J Geriatr Cardiol* 2015;12:668-75.
 52. Agatston AS, Janowitz WR, Hildner FJ, Zusmer NR, Viamonte M Jr, Detrano R. Quantification of coronary artery calcium using ultrafast computed tomography. *J Am Coll Cardiol* 1990;15:827-32.
 53. Hong C, Becker CR, Schoepf UJ, Ohnesorge B, Bruening R, Reiser MF. Coronary artery calcium: absolute quantification in non-enhanced and contrast-enhanced multi-detector row CT studies. *Radiology* 2002;223:474-80.
 54. Callister TQ, Cooil B, Raya SP, Lippolis NJ, Russo DJ, Raggi P. Coronary artery disease: improved reproducibility of calcium scoring with an electron-beam CT volumetric method. *Radiology* 1998;208:807-14.
 55. Greenland P, Alpert JS, Beller GA, et al. 2010 ACCF/AHA guideline for assessment of cardiovascular risk in asymptomatic adults: a report of the American College of Cardiology Foundation/American Heart Association Task Force on Practice Guidelines. *Circulation* 2010;122:e584-636.
 56. Hecht HS, Cronin P, Blaha MJ, et al. 2016 SCCT/STR guidelines for coronary artery calcium scoring of noncontrast noncardiac chest CT scans: a report of the Society of Cardiovascular Computed Tomography and Society of Thoracic Radiology. *J Thorac Imaging* 2017;32:W54-66.
 57. Chiles C, Duan F, Gladish GW, et al. Association of coronary artery calcification and mortality in the National Lung Screening Trial: a comparison of three scoring methods. *Radiology* 2015;276:82-90.
 58. Hughes-Austin JM, Dominguez A 3rd, Allison MA, et al. Relationship of coronary calcium on standard chest CT scans with mortality. *JACC Cardiovasc Imaging* 2016;9:152-9.
 59. Jacobs PC, Gondrie MJ, van der Graaf Y, et al. Coronary artery calcium can predict all-cause mortality and cardiovascular events on low-dose CT screening for lung cancer. *AJR Am J Roentgenol* 2012;198:505-11.
 60. Mets OM, Vliegenthart R, Gondrie MJ, et al. Lung cancer screening CT-based prediction of cardiovascular events. *JACC Cardiovasc Imaging* 2013;6:899-907.
 61. Pletcher MJ, Sibley CT, Pignone M, Vittinghoff E, Greenland P. Interpretation of the coronary artery calcium score in combination with conventional cardiovascular risk factors: the Multi-Ethnic Study of Atherosclerosis (MESA). *Circulation* 2013;128:1076-84.
 62. Peacock AJ, Murphy NF, McMurray JJV, Caballero L, Stewart S. An epidemiological study of pulmonary arterial hypertension. *Eur Respir J* 2007;30:104-9.
 63. Hachulla E, Gressin V, Guillemin L, et al. Early detection of pulmonary arterial hypertension in systemic sclerosis—a French nationwide prospective multicenter study. *Arthritis Rheum* 2005;52:3792-800.
 64. Machado RF, Gladwin MT. Pulmonary hypertension in hemolytic disorders pulmonary vascular disease: the global perspective. *Chest* 2010;137:30s-8s.
 65. Sitbon O, Lascoux-Combe C, Delfraissy JF, et al. Prevalence of HIV-related pulmonary arterial hypertension in the current antiretroviral therapy era. *Am J Resp Crit Care Med* 2008;177:108-13.
 66. Humbert M, Sitbon O, Chaouat A, et al. Pulmonary arterial hypertension in France—results from a national registry. *Am J Resp Crit Care Med* 2006;173:1023-30.
 67. Linguraru MG, Pura JA, Van Uitert RL, et al. Segmentation and quantification of pulmonary artery for noninvasive CT assessment of sickle cell secondary pulmonary hypertension. *Med Phys* 2010;37:1522-32.
 68. Pena E, Dennie C, Veinot J, Muniz SH. Pulmonary hypertension: how the radiologist can help. *Radiographics* 2012;32:9-32.
 69. Truong QA, Massaro JM, Rogers IS, et al. Reference values for normal pulmonary artery dimensions by noncontrast cardiac computed tomography: the Framingham Heart Study. *Circ Cardiovasc Imaging* 2012;5:147-54.
 70. Mahammedi A, Oshmyansky A, Hassoun PM, Thiemann DR, Siegelman SS. Pulmonary artery measurements in pulmonary hypertension: the role of computed tomography. *J Thorac Imaging* 2013;28:96-103.
 71. Zisman DA, Karlamangla AS, Ross DJ, et al. High-resolution chest CT findings do not predict the presence of pulmonary hypertension in advanced idiopathic pulmonary fibrosis. *Chest* 2007;132:773-9.
 72. Browne AM, Cronin CG, English C, NiMhuircheartaigh J, Murphy JM, Bruzzi JF. Unsuspected pulmonary emboli in oncology patients undergoing routine computed tomography imaging. *J Thorac Oncol* 2010;5:798-803.
 73. Gladish GW, Choe DH, Marom EM, Sabloff BS, Broemeling LD, Munden RF. Incidental pulmonary emboli in oncology patients: prevalence, CT evaluation, and natural history. *Radiology* 2006;240:246-55.
 74. Gosselin MV, Rubin GD, Leung AN, Huang J, Rizk NW. Unsuspected pulmonary embolism: prospective detection on routine helical CT scans. *Radiology* 1998;208:209-15.
 75. Storto ML, Di Credico A, Guido F, Larici AR, Bonomo L. Incidental detection of pulmonary emboli on routine MDCT of the chest. *AJR Am J Roentgenol* 2005;184:264-7.
 76. Mehta S, Helmersen D, Provencher S, et al. Diagnostic evaluation and management of chronic thromboembolic pulmonary hypertension: a clinical practice guideline. *Can Respir J* 2010;17:301-34.
 77. Kwek BH, Wittram C. Postpneumonectomy pulmonary artery stump thrombosis: CT features and imaging follow-up. *Radiology* 2005;237:338-41.
 78. Barbetakis N, Asteriou C, Kleontas A. Post-lobectomy pulmonary artery stump thrombosis: how dangerous is it? *Ann Thorac Surg* 2011;91:e44.
 79. Dury S, Toubas O, Delepine G, Deslee G, Lebagry F. [Pulmonary artery stump thrombosis following pneumonectomy]. *Rev Mal Respir* 2007;24:367-70.