

Management of Incidental Adnexal Findings on CT and MRI: A White Paper of the ACR Incidental Findings Committee

SA-CME

Maitray D. Patel, MD^a, Susan M. Ascher, MD^b, Mindy M. Horrow, MD^c, Perry J. Pickhardt, MD^d, Liina Poder, MD^e, Mindy Goldman, MD^f, Lincoln L. Berland, MD^g, Pari V. Pandharipande, MD, MPH^b, Katherine E. Maturen, MD, MS^{i, j}

Credits awarded for this enduring activity are designated “SA-CME” by the American Board of Radiology (ABR) and qualify toward fulfilling requirements for Maintenance of Certification (MOC) Part II: Lifelong Learning and Self-assessment. To access the SA-CME activity visit <https://cortex.acr.org/Presenters/CaseScript/CaseView?CDId=kDHaXjTjOzs%3d>. SA-CME credit for this article expires December 27, 2022.

Abstract

The ACR Incidental Findings Committee (IFC) presents recommendations for managing adnexal masses incidentally detected on CT and MRI. These recommendations represent an update of those provided in our previous *JACR* 2013 white paper. The Adnexal Subcommittee, which included six radiologists with subspecialty expertise in abdominal imaging or ultrasound and one gynecologist, developed this algorithm. The recommendations draw from published evidence and expert opinion and were finalized by iterative consensus. Algorithm branches successively categorize adnexal masses based on patient characteristics (eg, pre- versus postmenopausal) and imaging features. They terminate with a management recommendation. The algorithm addresses most, but not all, pathologies and clinical scenarios. Our goal is to improve quality of care by providing guidance on how to manage incidentally detected adnexal masses.

Key Words: Adnexal cyst, CT, incidental findings, MRI, ovarian cyst

J Am Coll Radiol 2020;17:248-254. Copyright © 2019 American College of Radiology

OVERVIEW OF THE ACR INCIDENTAL FINDINGS PROJECT

The core objectives of the Incidental Findings Project are to (1) develop consensus on patient characteristics and

imaging features that are required to characterize an incidental finding; (2) provide guidance to manage such findings in ways that balance the risks and benefits to patients; (3) recommend reporting terms that reflect the

^aDepartment of Radiology, Mayo Clinic Alix School of Medicine, Phoenix, Arizona.

^bDepartment of Radiology, Georgetown University Medical Center, Washington, DC.

^cDepartment of Radiology, Albert Einstein Medical Center, Philadelphia, Pennsylvania.

^dDepartment of Radiology, University of Wisconsin School of Medicine, Madison, Wisconsin.

^eDepartment of Radiology, University of California San Francisco, San Francisco, California.

^fDepartment of Obstetrics, Gynecology & Reproductive Sciences, University of California San Francisco, San Francisco, California.

^gDepartment of Radiology, University of Alabama at Birmingham, Birmingham, Alabama.

^hDepartment of Radiology, Institute for Technology Assessment, Massachusetts General Hospital, Boston, Massachusetts.

ⁱDepartment of Radiology, University of Michigan Medical School, Ann Arbor, Michigan.

^jDepartment of Obstetrics and Gynecology, University of Michigan Medical School, Ann Arbor, Michigan.

Corresponding author and reprints: Maitray D. Patel, MD, Mayo Clinic Arizona, Department of Radiology, 5777 E Mayo Blvd, Phoenix, AZ 85054; e-mail: patel.maitray@mayo.edu.

Dr Pandharipande reports grants from Medical Imaging and Technology Alliance, outside the submitted work. Dr Pickhardt reports personal fees from Bracco, other from SHINE, other from Elucent, outside the submitted work. The other authors state that they have no conflict of interest related to the material discussed in this article.

level of confidence regarding a finding; and (4) focus future research by proposing a generalizable management framework across practice settings.

THE CONSENSUS PROCESS: MANAGEMENT OF INCIDENTAL ADNEXAL MASSES

This article presents the ACR Incidental Findings Committee (IFC)'s updated recommendations for the management of incidental adnexal masses detected on CT or MRI. The material presented is updated from prior guidance from the ACR, published in 2013 [1]. The process of developing this algorithm included naming a subcommittee chair, who appointed subcommittee members that included recognized experts in pelvic imaging, incidental findings, or the management of patients at risk for an adnexal mass. The subcommittee then developed and gained consensus on preliminary recommendations. The subcommittee used published evidence as their primary source. When evidence was not available, they invoked the collective expertise of their team. The preliminary algorithm underwent review by additional members within the IFC, including the Body Commission chair and the IFC chair. The revised algorithm and corresponding white paper draft were submitted to additional ACR stakeholders to gain input and feedback. Consensus was obtained iteratively after successive reviews and revisions. After completion of this process, the algorithm and white paper were finalized. The IFC's consensus processes meet policy standards of the ACR. However, they do not meet any specific, formal national standards. This algorithm and set of recommendations do not represent policy of the ACR Practice Guidelines or the ACR Appropriateness Criteria. Our consensus may be termed "guidance" and "recommendations" rather than "guidelines," which has a more formal definition.

ELEMENTS OF THE FLOWCHARTS: COLOR CODING

The algorithm is encapsulated in a flowchart. Within the flowchart, yellow boxes indicate using or acquiring clinical data (eg, lesion size), green boxes describe recommendations for action (eg, follow-up imaging), and red boxes indicate that work-up or follow-up may be terminated (eg, if the finding is presumed to be benign). To minimize complexity, each algorithm addresses most—but not all—imaging appearances and clinical scenarios. Radiologists should feel comfortable deviating from the algorithm in circumstances that are not represented in the

algorithm, based on the specific imaging appearance of the finding in question and patient characteristics—the algorithm content must be viewed as *recommendations* and should not be considered as "standard of care."

NATURE AND SCOPE OF THE PROBLEM

Incidental adnexal findings are commonly identified in women on CT and MR studies that include the pelvis [2-4]. Normal physiologic changes in premenopausal women include monthly development of a dominant follicle and subsequent corpus luteum, resulting in a potential incidental CT or MR finding in many premenopausal women [5]. Nonneoplastic cysts that may wax and wane in size are also common in postmenopausal women; in a large series of postmenopausal women, 14% had cysts on an initial ultrasound examination, with 32% resolving but 8% developing a new cyst at 1-year follow-up [6]. In a large CT colonography program, investigators reported that among 2,869 consecutive women aged 50 or older who underwent screening, none of the 118 women (4.1%) with an incidental adnexal mass on unenhanced CT colonography were found to have ovarian cancer [3]. Incidental adnexal masses are detected even when pelvic coverage on an imaging examination is incomplete; Zidan et al found that 4 of 194 women (2%) had ovarian cysts in their study of incidental extraspinal findings on lumbar spine MR examinations [4].

An extensive body of ultrasound-based imaging literature in surgical and clinically followed cohorts shows that the risk of malignancy in simple cysts identified sonographically is negligible in both premenopausal and postmenopausal women [7], a conclusion confirmed by recent large studies showing no increased risk of malignancy in women with sonographically identified simple adnexal cysts irrespective of cyst size [6-9]. In fact, invasive ovarian serous cystadenocarcinoma is now known to primarily arise from solid precursors in the fallopian tube, not the ovary [10]; this understanding supports the conclusion that simple ovarian cysts are not precursors to ovarian carcinoma.

Based on this evidence, the Society of Radiologists in Ultrasound (SRU) has revised consensus recommendations for the management of sonographically identified incidental adnexal simple cysts [7]. Even with the understanding that simple adnexal cysts have negligible risk of malignancy, two primary concepts justify an approach in which some adnexal simple cysts on ultrasound merit a short period of continued surveillance, even when asymptomatic. First, as with any imaging observation, there is a small risk of

mischaracterization, so the conclusion that an adnexal cyst is simple might be incorrect. Second, some simple adnexal cysts are benign ovarian neoplasms (cystadenomas) and may grow at a rate that would eventually result in clinical attention even if initially asymptomatic; patients and providers may benefit from knowing that rate of growth so that appropriate clinical follow-up can be employed. These considerations must be balanced by the potential harms introduced by imaging surveillance of likely benign findings, including increased likelihood of unnecessary surgical intervention as well as increased patient and provider anxiety and health care costs [11]. Size (maximum cyst diameter) plays an important role in determining which simple adnexal cysts might benefit most from sonographic surveillance, targeting those more likely to be benign neoplasms rather than nonneoplastic cysts. The revised SRU consensus recommendations have increased some size thresholds for surveillance, now stating that simple cysts characterized with standard ultrasound quality do not require ultrasound follow-up when ≤ 5 cm in premenopausal women and ≤ 3 cm in postmenopausal women [7]. When there is exceptional quality and documentation that the cyst is simple, the SRU panel opines that these thresholds are justifiably increased to ≤ 7 cm in premenopausal women and ≤ 5 cm in postmenopausal women, because the risk of mischaracterization is reduced [7]. The revised SRU consensus recommendation is an important backdrop to this revision of the IFC's recommendations related to the management of incidental adnexal findings on CT and MR.

REPORTING CONSIDERATIONS

The following four elements should be reported when an incidental adnexal mass is detected on CT or MRI:

1. Mass characteristics (ie, simple-appearing cyst, features indicating a specific diagnosis, indeterminate features)
2. Size (largest diameter)
3. Technical considerations
4. Known or presumed menopausal status

Mass Characteristics

In broad terms, an adnexal mass identified on CT or MRI can be placed into one of three categories: (1) a simple-appearing cyst; (2) a mass that is not a simple-appearing cyst but with characteristic features allowing presumptive diagnosis; (3) a mass with features not allowing for confident diagnosis (uncertain diagnosis).

The term "simple cyst" has been used for sonographically characterized cysts that are round or oval, with smooth thin walls, no solid component or septation, and

no internal flow using color Doppler imaging [12]. In the female pelvis, these are called ovarian simple cysts when shown to clearly arise from the ovary, and they are called adnexal simple cysts when the structure of origin is uncertain because ovarian parenchyma is not visualized (these are still usually presumed to have arisen from the ovary) [12]. To distinguish from this sonographically derived nomenclature, the term "simple-appearing cyst" is used to describe a round or ovoid fluid-density mass on CT or fluid-signal cyst on MR without a solid component, with smooth, imperceptible, or thin walls; this terminology replaces the "benign-appearing cyst" term used in the prior IFC 2013 recommendations regarding incidental adnexal findings [1,13]. On CT, multiple regions of interest should be examined within different portions of the suspected cyst to be assured that the mass is of fluid density; attenuation values between -10 and 20 Hounsfield units (HU) are considered fluid density [14]. On MR, fluid signal intensity is determined by comparison with other fluid containing structures such as the bladder and, broadly speaking, includes hyperintense signal on T2-weighted images, hypointense signal on T1-weighted images, and absent postcontrast enhancement.

As outlined in the prior IFC white paper on incidental adnexal findings [1], some adnexal masses on CT, and to a larger extent MRI, can show imaging features that are characteristic for a particular diagnostic entity [1,15]. Benign examples include some hemorrhagic corpus luteal cysts, para-ovarian or paratubal cysts, hydrosalpinges, peritoneal inclusion cysts, ovarian fibromas, subserosal or pedunculated uterine leiomyomas, endometriomas, and dermoids [1,16]. Some CT and MR findings are also characteristic of ovarian or adnexal malignancy [17]. It is important that radiologists who report CT or MR studies of the pelvis be familiar with the features of adnexal masses that enable confident benign or malignant diagnosis, so that those features can be described in the reporting of these masses. Some of these features were described in Table 1 in the prior IFC Adnexal 2013 article [1] and have been the focus of other publications [18,19].

When an incidental adnexal mass on CT or MR cannot be characterized as a simple-appearing cyst and does not have characteristic imaging features for specific adnexal pathology, the diagnosis is uncertain.

Size

For incidental adnexal masses on CT or MR, only the largest single diameter needs to be reported when the

Table 1. Management recommendations for adnexal masses with characteristic features on CT or MR

Adnexal Mass	Premenopausal (or Age < 50 If Unknown)	Postmenopausal (or Age ≥ 50 If Unknown)
Hemorrhagic cyst		US or MRI to characterize*
≤5 cm	No further imaging	
>5 cm	US follow-up in 2-3 months	
Para-ovarian cyst	Usually further imaging is unnecessary; clinical management	
Peritoneal inclusion cyst		
Simple hydrosalpinx		
Ovarian fibroma		
Uterine leiomyoma		
Endometrioma	Usually managed by gynecologist, may require periodic imaging	
Dermoid		
Suspected malignancy	US or MRI to characterize*	

US = ultrasound.

*The study should be performed promptly for further evaluation, rather than in follow-up to assess temporal changes.

mass is round or ovoid in shape or the conclusion is that the mass does not need further imaging or follow-up. Reporting three orthogonal dimensions is helpful when the mass has a more irregular shape, especially when imaging follow-up will be recommended.

Technical Considerations

Relevant technical limitations in the assessment of the incidental mass should be reported. These may include low signal-to-noise ratio, artifacts (eg, from hip prostheses), lack of intravenous contrast, and incomplete anatomic coverage; any mass imaged with these constraints should be described as having “limited assessment.” At the other end of the spectrum, MR has excellent diagnostic accuracy for adnexal mass characterization when it includes the following three elements: (1) T2-weighted images; (2) pre- and postcontrast T1-weighted images; and (3) complete anatomic coverage of the mass in at least two imaging planes. In this scenario, reporting of the incidental adnexal mass should indicate that the mass has been “fully characterized” with MR, because this influences subsequent imaging recommendations.

Known or Presumed Menopausal Status

If available, the menopausal status should be included as part of the report when it impacts recommended management of incidental adnexal findings. When not available, as previously recommended in the IFC Adnexal 2013 approach, 50 years of age can be used as a surrogate landmark, with those findings in women less than 50 years of age managed as if premenopausal, and those findings in women 50 years of age or greater managed as if postmenopausal [1]. Because the average age of menopause in the United States is 51 years, this will

tend to apply more conservative size thresholds for follow-up of simple-appearing cysts in patients who are just at or slightly over 50 years of age with unknown menopausal status.

INCLUSION AND EXCLUSION CRITERIA FOR USE OF THE ALGORITHM

This algorithm should be applied to incidentally detected adnexal masses >1 cm in maximum diameter in women after menarche; in keeping with the prior IFC 2013 algorithm, adnexal findings ≤1 cm are not included because subcentimeter cysts (often follicles) are ubiquitous in premenopausal women, extremely common in postmenopausal women, and often too small to characterize on CT or MR [1,5]. Because the average age of menarche in the United States is between 12 and 13 years, age 16 may be used as a conservative estimate for assuming menarche. The algorithm does not apply to any CT or MR adnexal finding that is unchanged in appearance over 2 or more years, because malignancy is effectively excluded by this stability [20]. The algorithm is not intended for use in women at high genetic risk for ovarian cancer, in whom lower size thresholds for sonographic characterization of adnexal cysts may be justified. The algorithm is aborted when a patient develops symptoms potentially related to a mass being followed; an asymptomatic cyst may become painful because of internal hemorrhage, rupture, or torsion, with symptoms justifying immediate imaging attention [21]. Adnexal masses 10 cm or larger in diameter are unlikely to be asymptomatic and are very unlikely to be related to normal physiology [22]. For such masses, full characterization with MR may be better than ultrasound, because ultrasound may have limitations because of the size of the mass.

IMPLICATIONS OF IMAGING AND CLINICAL FEATURES

Basic Principles of the Algorithm

1. Simple-appearing cysts on CT or MR have very low risk of malignancy. Sonographically identified simple adnexal cysts have very low, if any, risk of malignancy, irrespective of cyst size [6-9]. There is good reason to believe that simple-appearing cysts on CT and MR have similarly very low risk of malignancy [3]. MR has long been known to have high specificity in the characterization of adnexal masses, with diagnostic performance for benign cystic lesions comparable to ultrasound with Doppler [23]. For CT, since prior publication of the IFC 2013 recommendations, Baheti et al evaluated the agreement between contrast-enhanced CT and ultrasound in characterizing adnexal masses and showed that simple-appearing cysts on CT correspond to simple cysts on ultrasound [24]. A subsequent investigation also showed that simple-appearing cysts on CT had no risk of malignancy [25]. Thus, although there is far more evidence confirming the absence of increased malignancy risk in sonographically characterized simple adnexal cysts, based on the available current evidence, it is reasonable to assume that simple-appearing cysts on CT or MR are similarly benign.
2. Small, incidental, simple-appearing adnexal cysts on CT or MR do not justify sonographic characterization even when assessment is limited. Paralleling the revised SRU consensus recommendations for incidental simple cysts on ultrasound, our committee consensus uses ≤ 3 cm (postmenopausal) and ≤ 5 cm (premenopausal) as the default threshold for not pursuing follow-up of incidental simple-appearing cysts on CT or MR [7]. Because many adnexal cysts are ≤ 5 cm in premenopausal women and ≤ 3 cm in postmenopausal women, the mere existence of a small (ie, below size threshold) simple-appearing cyst with limited assessment is not enough to justify sonographic recharacterization or follow-up when it is an incidental finding. On the other hand, sonographic characterization of incidental simple-appearing cysts on CT or MR >3 cm (postmenopausal) or >5 cm (premenopausal) is justified when assessment is limited, because cysts of this size are less common and the likelihood of CT or MR mischaracterization may be higher.
3. The optimal timing of sonographic follow-up of larger simple-appearing cysts balances the small risk of CT or MR mischaracterization against the desire to gain information about cyst growth with as few imaging studies as possible. The distinction between recommending ultrasound to characterize an adnexal mass and recommending ultrasound follow-up of an adnexal mass identified on CT or MR is important [5]. The former is intended to better demonstrate cyst contents and the latter to provide surveillance over time. When an incidental simple-appearing cyst is adequately characterized by CT or MR but justifies sonographic follow-up because of its size, the sonographic evaluation is reasonably delayed by 6 to 12 months to provide evidence regarding the cyst growth rate. By delaying the sonographic follow-up by 6 to 12 months instead of immediately recharacterizing the cyst with ultrasound, the cyst has a chance to resolve or involute, allowing for diagnosis as a nonneoplastic cyst that requires no further follow-up, or to grow, favoring a benign cystic neoplasm. However, the desire to wait at least 6 to 12 months to more confidently assess cyst resolution, involution, or growth never takes precedence over new symptoms, which may reflect cyst hemorrhage, rupture, or torsion; luckily, these developments are uncommon, occurring in less than 1% of cases [21].
4. Fully characterized simple-appearing cysts on MR have very low risk of mischaracterization, justifying higher size thresholds for pursuing follow-up. Similar to the approach taken by the revised SRU consensus recommendations, when an incidental simple-appearing cyst has already been fully characterized (as defined in the "Technical Considerations" subsection), the committee reasoned that the risk of mischaracterization is substantially reduced, justifying a higher threshold for sonographic follow-up: >5 cm for postmenopausal women and >7 cm for premenopausal women. For such masses, imaging follow-up serves only as a measure of the rate of cyst enlargement to inform subsequent clinical management.
5. CT or MR may show characteristic features of an adnexal mass that enable confident diagnosis of a specific entity. Table 1 outlines typical management strategies employed when an adnexal mass has CT or MRI features characteristic of specific adnexal pathology.

Overview of the Algorithm

Figure 1 addresses the gamut of incidental adnexal masses on CT or MR over 1 cm and without documented stability for 2 or more years. Because follicles and other cysts ≤ 1 cm are pervasive in normal premenopausal

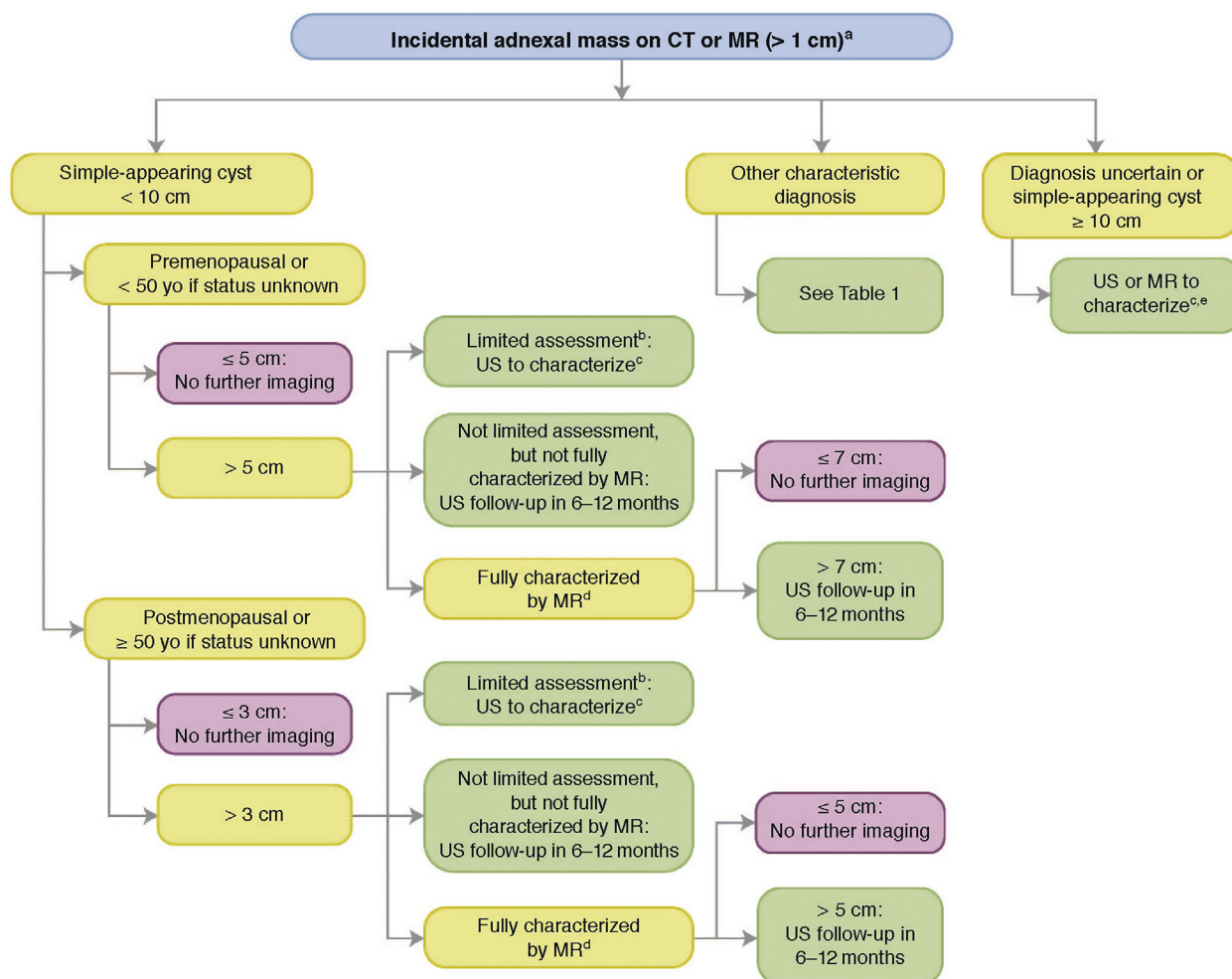


Fig 1. Management of incidental adnexal masses detected on CT or MR. ^aExclusions: (1) normal findings, including crenulated enhancing wall of corpus luteum, asymmetric ovary without mass, with normal shape; (2) calcifications without associated noncalcified mass; (3) previous characterization with ultrasound (US) or MRI; or (4) documented stability in size and appearance for 2 years. ^bLimited assessment on CT or MR: As defined in the article, this means the cyst is consistent with a simple-appearing cyst, but characterization is limited by low signal-to-noise ratio, artifact, lack of contrast assessment, or incomplete anatomic coverage. ^cUS or MRI to characterize means that the study should be performed promptly for further evaluation, rather than in follow-up to assess temporal changes. ^dFully characterized by MR: As defined in the article, this means the cyst has been characterized with (1) T2-weighted images; (2) pre- and postcontrast T1-weighted images; and (3) complete anatomic coverage in at least two imaging planes. ^eAssumes mass has not already been fully characterized by MR. Yellow boxes indicate using or acquiring clinical data (eg, lesion size), green boxes describe recommendations for action (eg, follow-up imaging), and red boxes indicate that work-up or follow-up may be terminated (eg, if the finding is presumed to be benign).

ovaries (some with hemorrhage), common in postmenopausal women, and potentially too small to characterize, these incidental findings are not included. Furthermore, adnexal findings that have demonstrated stability in appearance and size over 2 or more years are not ovarian malignancies; the ultrasound literature shows that these malignancies demonstrate change in 7 months or less [20]. Radiologists should be familiar with CT and MR features of normal ovarian physiology and inconsequential findings, including crenulated

enhancement of the wall of a corpus luteum, minor asymmetry of ovarian size when no mass is present, and adnexal calcifications without mass [5,26,27]. When an incidental adnexal mass has an uncertain diagnosis, ultrasound is usually the first imaging test for further characterization, but there may be instances in which contrast-enhanced MRI is preferred [28]. For example, a mass ≥ 10 cm in diameter may be too large for optimal sonographic characterization, justifying contrast-enhanced MR to further evaluate.

TAKE-HOME POINTS

- Incidental adnexal findings on CT and MR examinations of the female pelvis are common; we provide an algorithm to guide management of the incidental adnexal mass based on whether the mass is (1) a simple-appearing cyst; (2) has reasonably diagnostic imaging features; or (3) has an uncertain diagnosis.
- Simple-appearing cysts on CT or MR have very low risk of malignancy. Imaging follow-up is justified only when the cyst is relatively large for the patient's menopausal status. The primary goals of imaging follow-up are to limit the risk of cyst mischaracterization and to understand the rate of cyst growth, which may inform subsequent clinical decision making.
- Recommendations regarding the optimal timing of sonographic follow-up for a large simple-appearing cyst balances the small potential risk of CT or MR mischaracterization against the desire to gain information about cyst growth using as few imaging studies as possible.

REFERENCES

1. Patel MD, Ascher SM, Paspulati RM, et al. Managing incidental findings on abdominal and pelvic CT and MRI, part 1: white paper of the ACR Incidental Findings Committee II on adnexal findings. *J Am Coll Radiol* 2013;10:675-81.
2. Pooler BD, Kim DH, Pickhardt PJ. Indeterminate but likely unimportant extracolonic findings at screening CT colonography (C-RADS category E3): incidence and outcomes data from a clinical screening program. *AJR Am J Roentgenol* 2016;207:996-1001.
3. Pickhardt PJ, Hanson ME. Incidental adnexal masses detected at low-dose unenhanced CT in asymptomatic women age 50 and older: implications for clinical management and ovarian cancer screening. *Radiology* 2010;257:144-50.
4. Zidan MMA, Hassan IA, Elnour AM, et al. Incidental extraspinal findings in the lumbar spine during magnetic resonance imaging of intervertebral discs. *Heliyon* 2018;4:e00803.
5. Patel MD, Dubinsky TJ. Reimaging the female pelvis with ultrasound after CT: general principles. *Ultrasound Q* 2007;23:177-87.
6. Greenlee RT, Kessel B, Williams CR, et al. Prevalence, incidence, and natural history of simple ovarian cysts among women >55 years old in a large cancer screening trial. *Am J Obstet Gynecol* 2010;202: 373. e371-9.
7. Levine D, Patel MD, Suh-Burgmann EJ, et al. Simple adnexal cysts: SRU Consensus Conference update on follow-up and reporting. *Radiology* 2019;293(2):359-71.
8. Sharma A, Gentry-Maharaj A, Burnell M, et al. Assessing the malignant potential of ovarian inclusion cysts in postmenopausal women within the UK Collaborative Trial of Ovarian Cancer Screening (UKCTOCS): a prospective cohort study. *BJOG* 2012;119: 207-19.
9. Smith-Bindman R, Puder L, Johnson E, Miglioretti DL. Risk of malignant ovarian cancer based on ultrasonography findings in a large unselected population. *JAMA Intern Med* 2019;179:71-7.
10. Erickson BK, Conner MG, Landen CN Jr. The role of the fallopian tube in the origin of ovarian cancer. *Am J Obstet Gynecol* 2013;209: 409-14.
11. Grossman DC, Curry SJ, Owens DK, et al. Screening for Ovarian Cancer: US Preventive Services Task Force Recommendation Statement. *JAMA* 2018;319:588-94.
12. Levine D, Brown DL, Andreotti RF, et al. Management of asymptomatic ovarian and other adnexal cysts imaged at US: Society of Radiologists in Ultrasound Consensus Conference Statement. *Radiology* 2010;256:943-54.
13. Boos J, Brook OR, Fang J, Brook A, Levine D. Ovarian cancer: prevalence in incidental simple adnexal cysts initially identified in CT examinations of the abdomen and pelvis. *Radiology* 2018;286:196-204.
14. O'Connor SD, Silverman SG, Ip IK, Maehara CK, Khorasani R. Simple cyst-appearing renal masses at unenhanced CT: can they be presumed to be benign? *Radiology* 2013;269:793-800.
15. Kalish GM, Patel MD, Gunn ML, Dubinsky TJ. Computed tomographic and magnetic resonance features of gynecologic abnormalities in women presenting with acute or chronic abdominal pain. *Ultrasound Q* 2007;23:167-75.
16. Griffin N, Grant LA, Sala E. Adnexal masses: characterization and imaging strategies. *Semin Ultrasound CT MR* 2010;31:330-46.
17. Iyer VR, Lee SI. MRI, CT, and PET/CT for ovarian cancer detection and adnexal lesion characterization. *AJR Am J Roentgenol* 2010;194: 311-21.
18. Thomassin-Naggara I, Aubert E, Rockall A, et al. Adnexal masses: development and preliminary validation of an MR imaging scoring system. *Radiology* 2013;267:432-43.
19. Forstner R, Thomassin-Naggara I, Cunha TM, et al. ESUR recommendations for MR imaging of the sonographically indeterminate adnexal mass: an update. *Eur Radiol* 2017;27:2248-57.
20. Suh-Burgmann E, Hung YY, Kinney W. Outcomes from ultrasound follow-up of small complex adnexal masses in women over 50. *Am J Obstet Gynecol* 2014;211 623.e621-7.
21. Froyman W, Landolfo C, De Cock B, et al. Risk of complications in patients with conservatively managed ovarian tumours (IOTA5): a 2-year interim analysis of a multicentre, prospective, cohort study. *Lancet Oncol* 2019;20:448-58.
22. Schallert EK, Abbas PI, Mehollin-Ray AR, Price MC, Dietrich JE, Orth RC. Physiologic ovarian cysts versus other ovarian and adnexal pathologic changes in the preadolescent and adolescent population: US and surgical follow-up. *Radiology* 2019;292:172-8.
23. Sohaib SA, Mills TD, Sahdev A, et al. The role of magnetic resonance imaging and ultrasound in patients with adnexal masses. *Clin Radiol* 2005;60:340-8.
24. Baheti AD, Lewis CE, Hippe DS, O'Malley RB, Wang CL. Imaging characterization of adnexal lesions: do CT findings correlate with US? *Abdom Radiol (NY)* 2018;43:1764-71.
25. Baheti AD, Lewis CE, Hippe DS, O'Malley RB, Wang CL. Adnexal lesions detected on CT in postmenopausal females with non-ovarian malignancy: do simple cysts need follow-up? *Abdom Radiol (NY)* 2019;44:661-8.
26. Borders RJ, Breiman RS, Yeh BM, Qayyum A, Coakley FV. Computed tomography of corpus luteal cysts. *J Comput Assist Tomogr* 2004;28:340-2.
27. Shin YM, Lee JK, Turan N, Mauro D, Chong W. Computed tomography appearance of ovarian cysts with hyperenhancing rim during the menstrual cycle in women of different ages. *J Comput Assist Tomogr* 2010;34:532-6.
28. Atri M, Abdullah A, Reinhold C, et al. ACR Appropriateness Criteria® clinically suspected adnexal mass, no acute symptoms. *J Am Coll Radiol* 2019;16:S77-93.